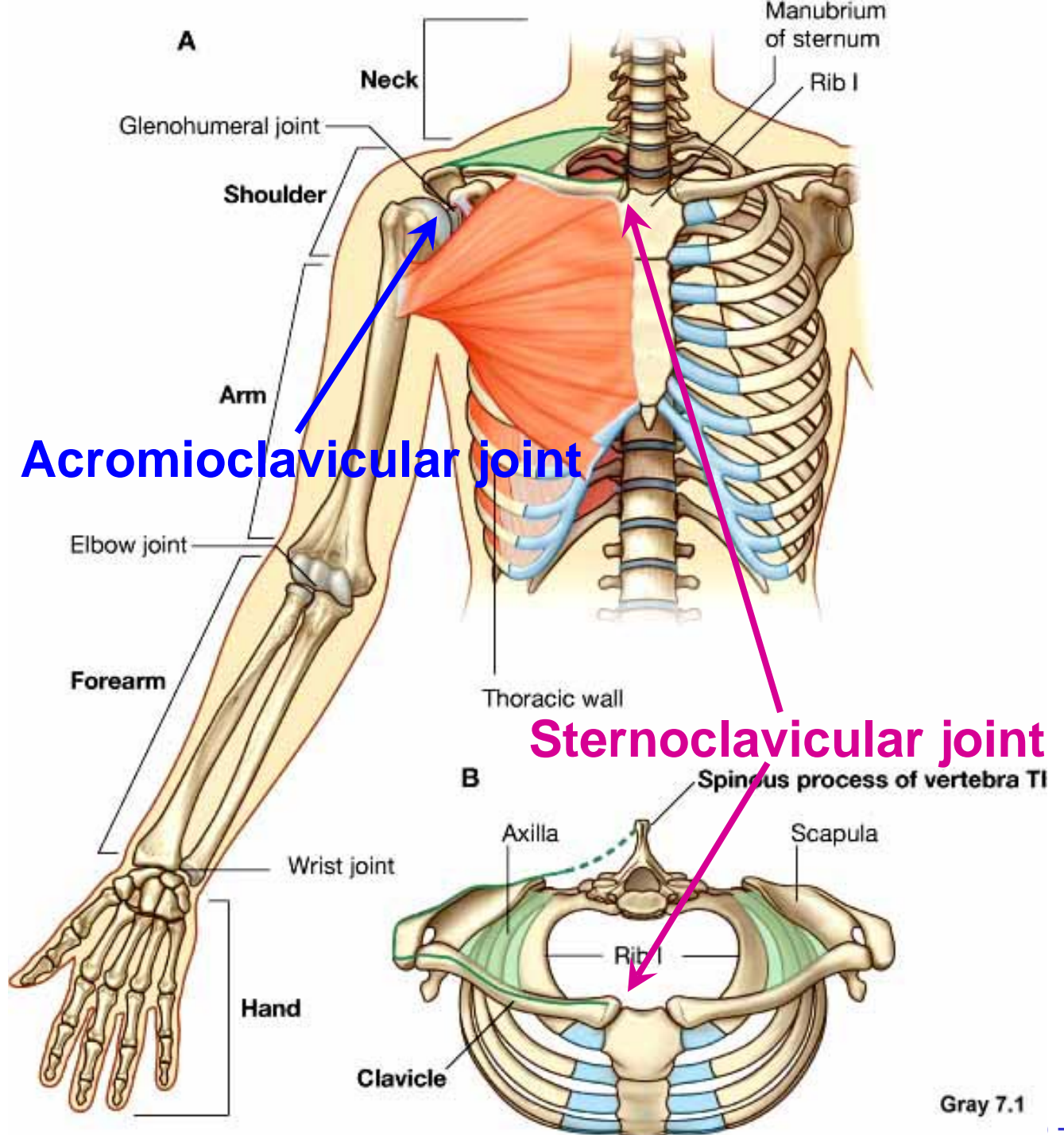


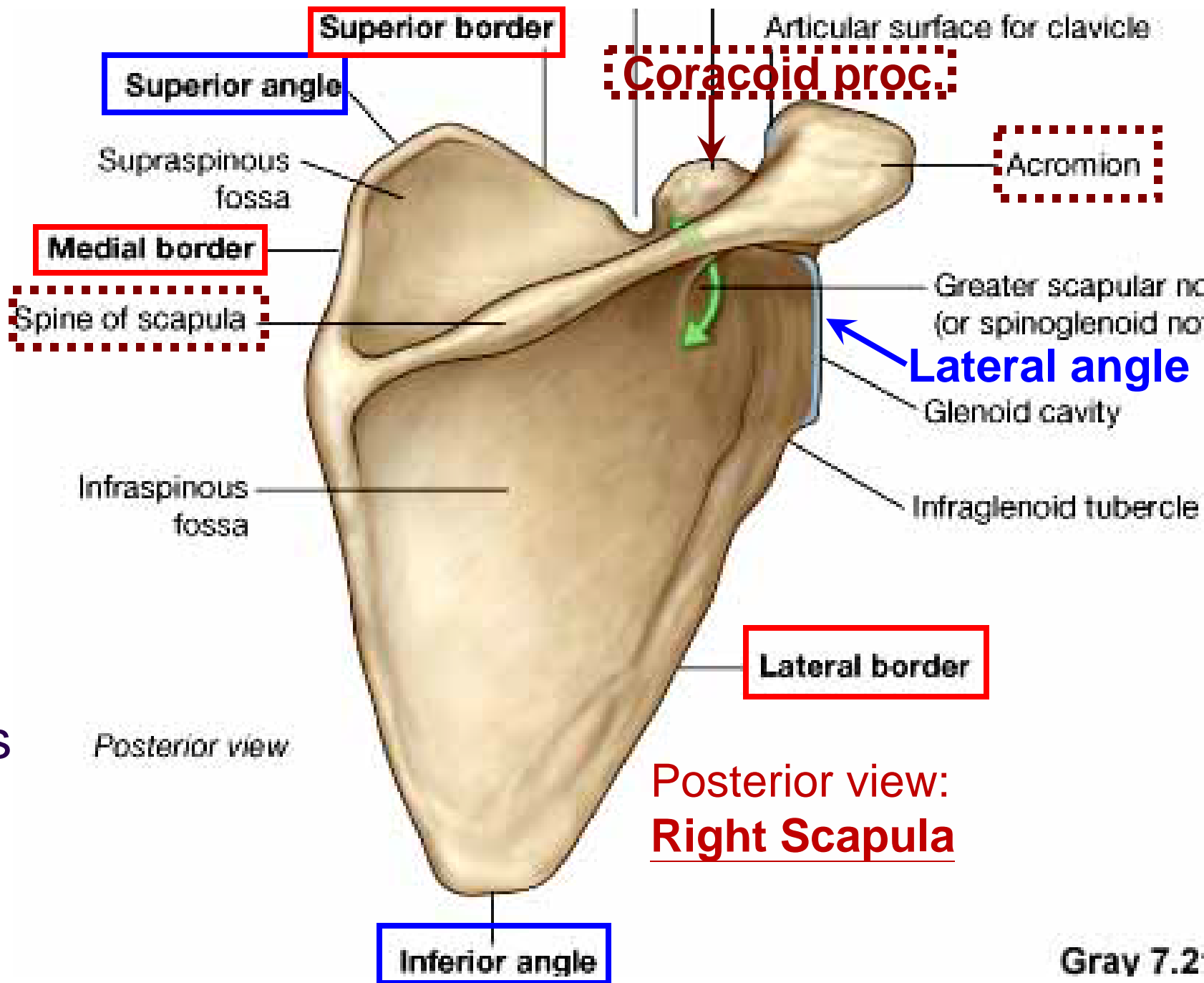
Shoulder

- Pectoral girdle (shoulder girdle)
- Scapula
- proximal end of Humerus
- Clavicle



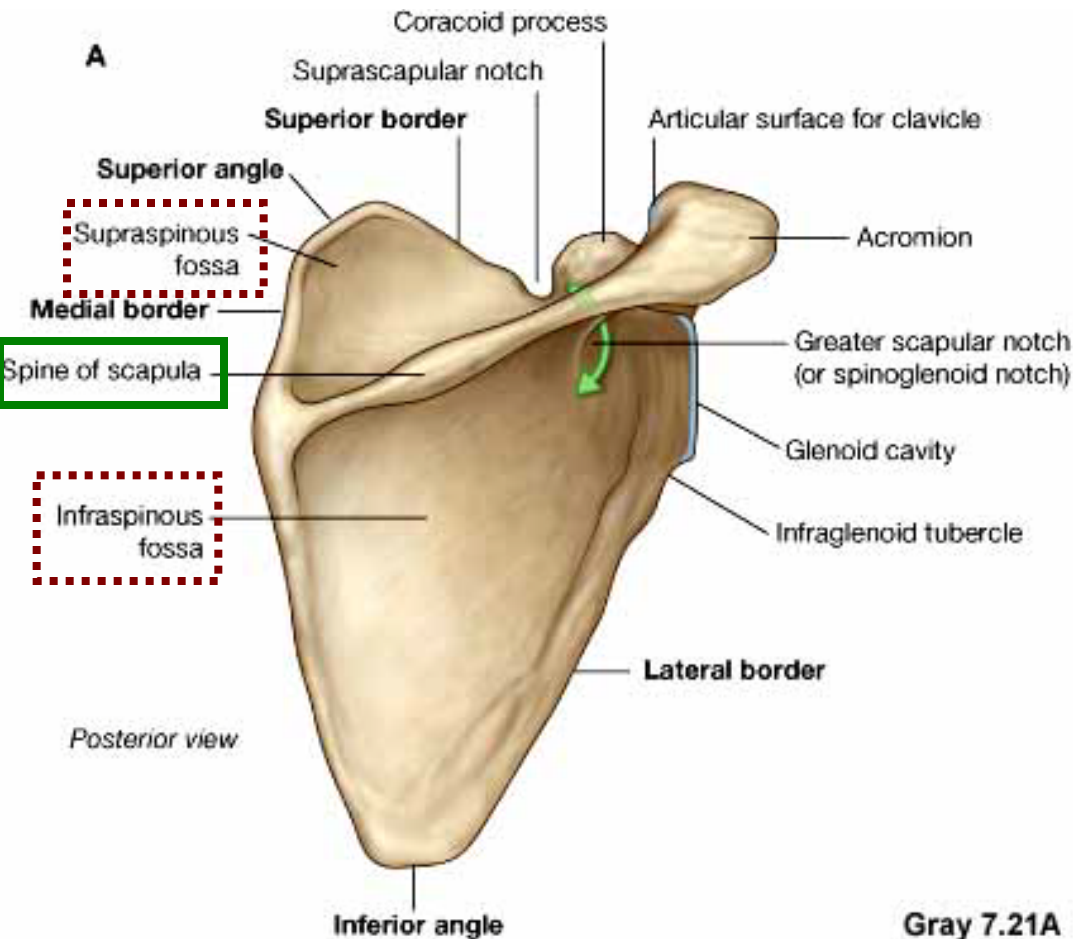
Scapula

- 3 angles
 - Superior
 - Inferior
 - Lateral
- 3 borders
 - Medial
 - Lateral
 - Superior
- 2 surfaces
- 3 processes
 - Acromion
 - Spine
 - Coracoid

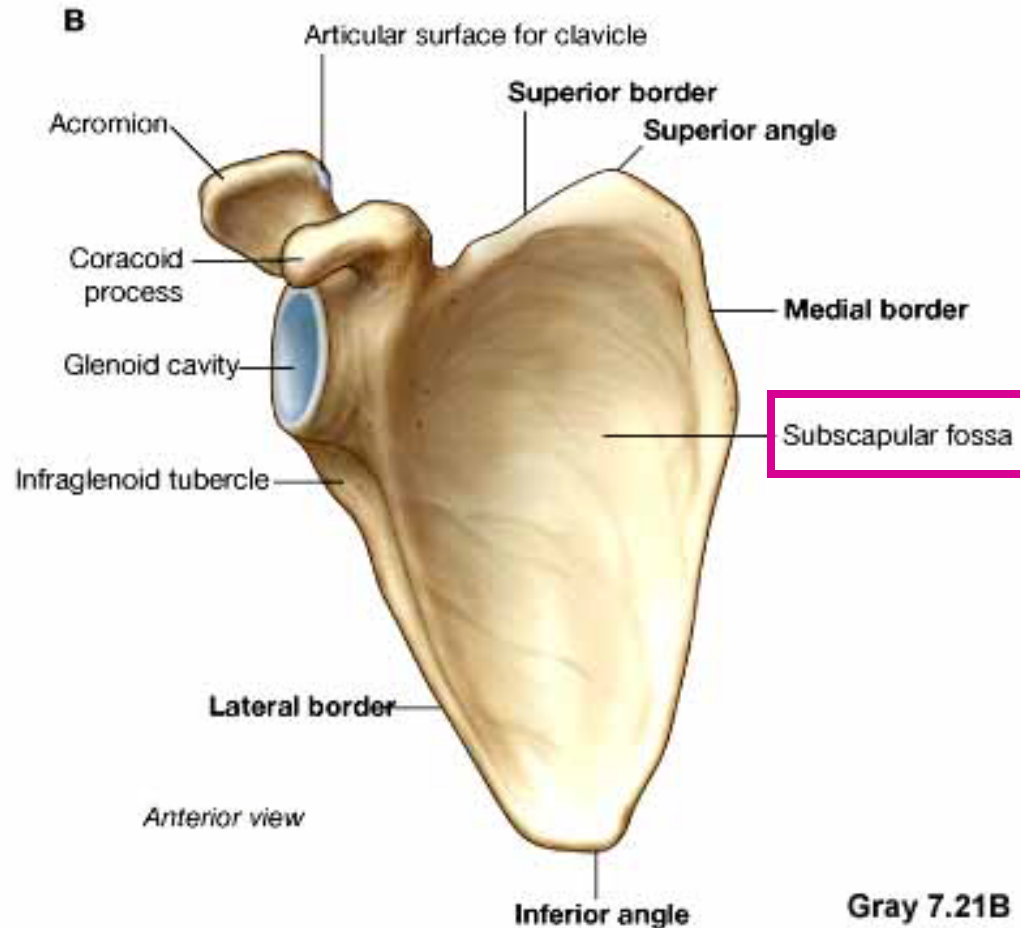


Scapula • 2 surfaces: Costal (Anterior), Posterior

Posterior view: Right Scapula

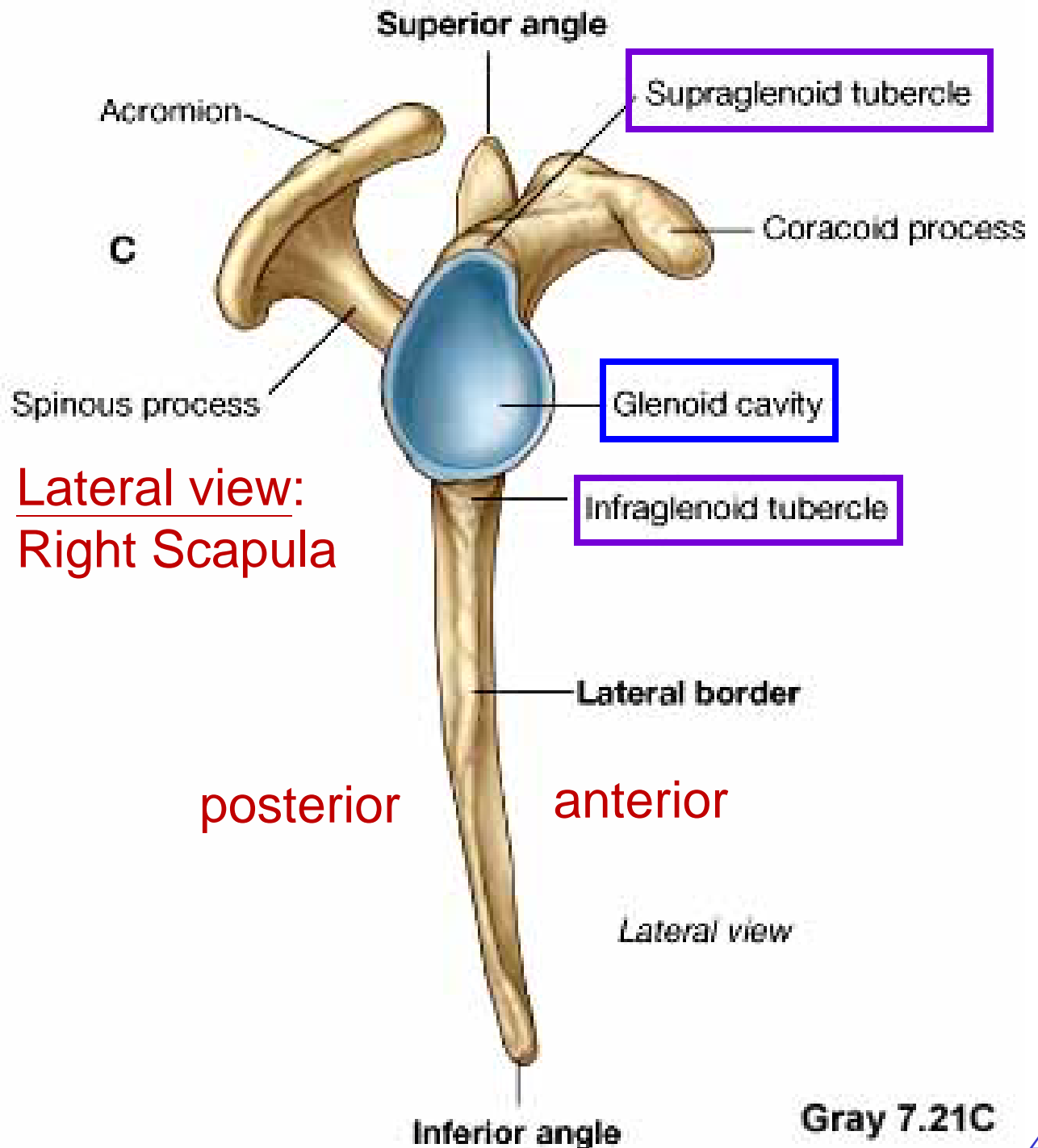


Costal (Anterior) view: Right Scapula



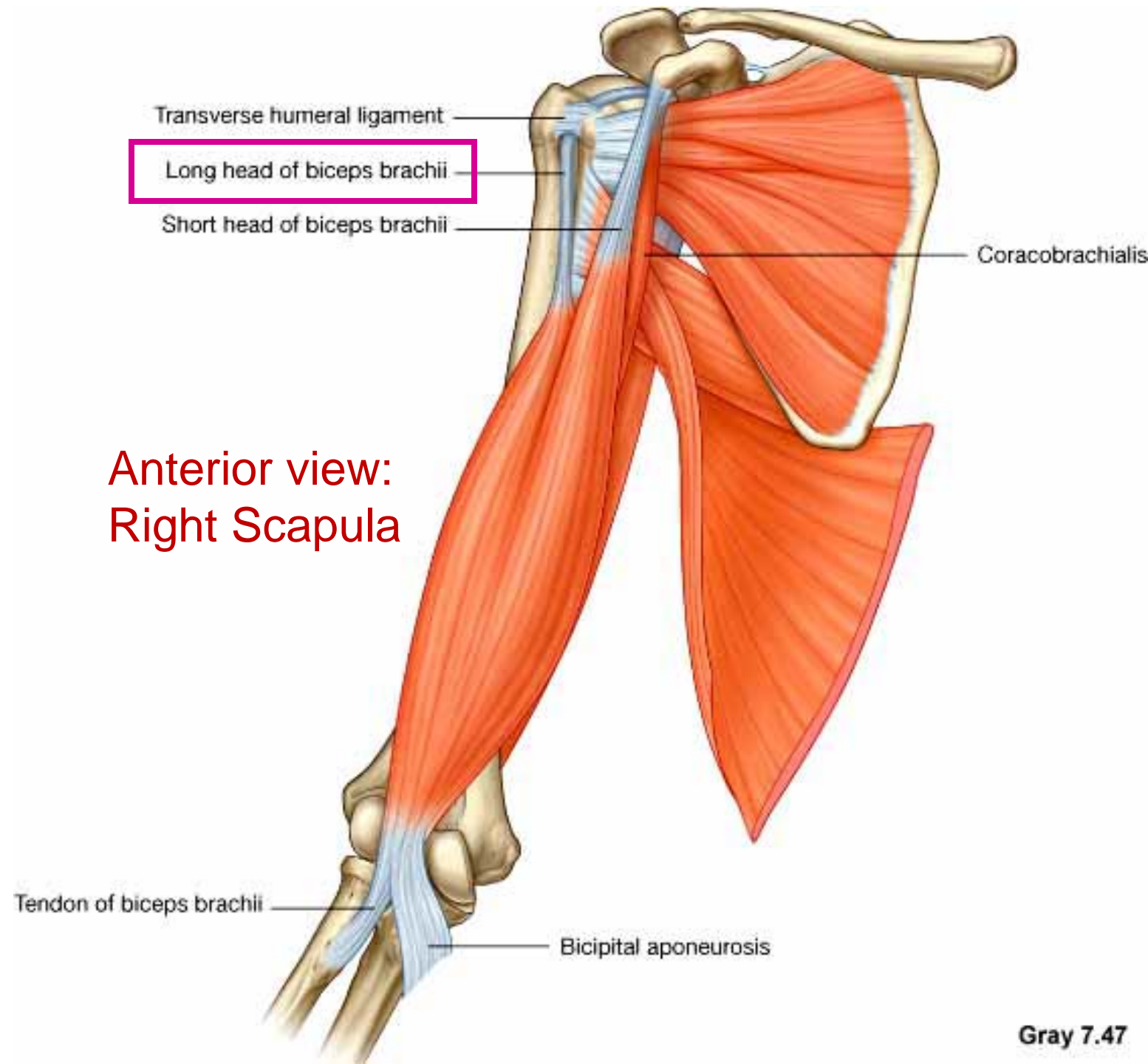
Scapula

- Glenoid cavity:
Glenohumeral joint
- Infraglenoid tubercle
- Supraglenoid tubercle



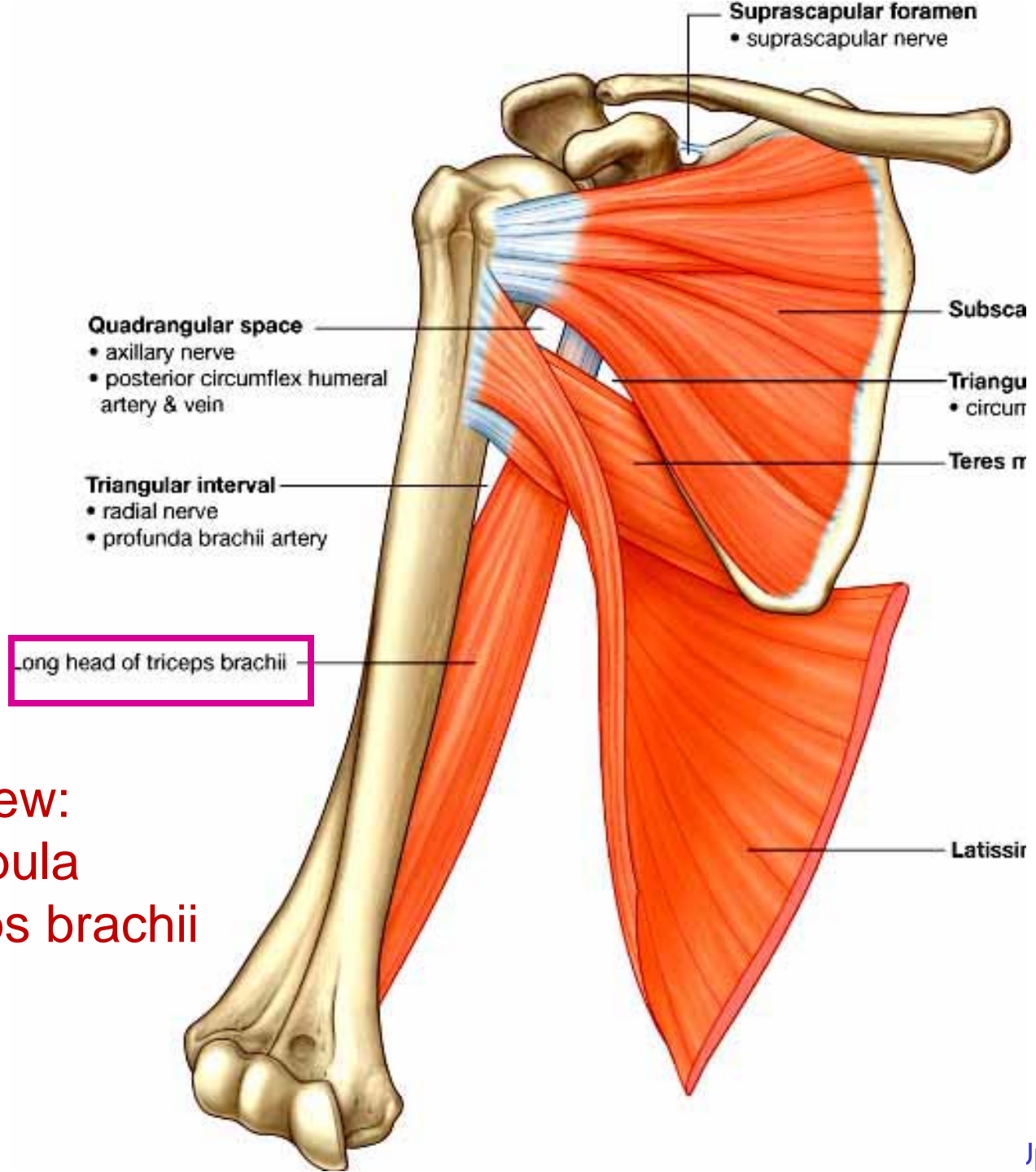
Scapula

- Supraglenoid tubercle: long head of biceps brachii



Scapula

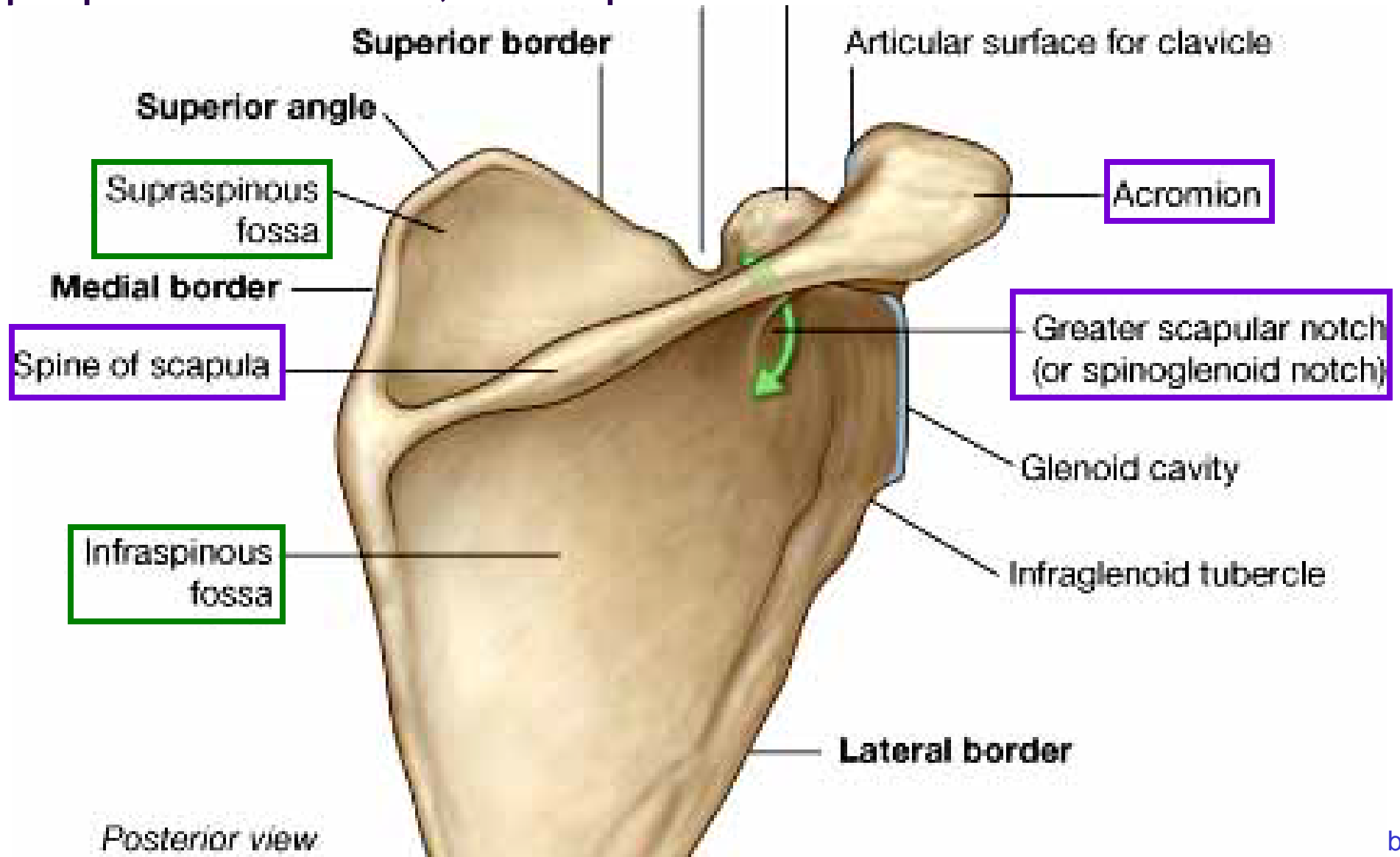
- Infraglenoid tubercle: long head of triceps brachii



Anterior view:
Right Scapula
(with biceps brachii
removed)

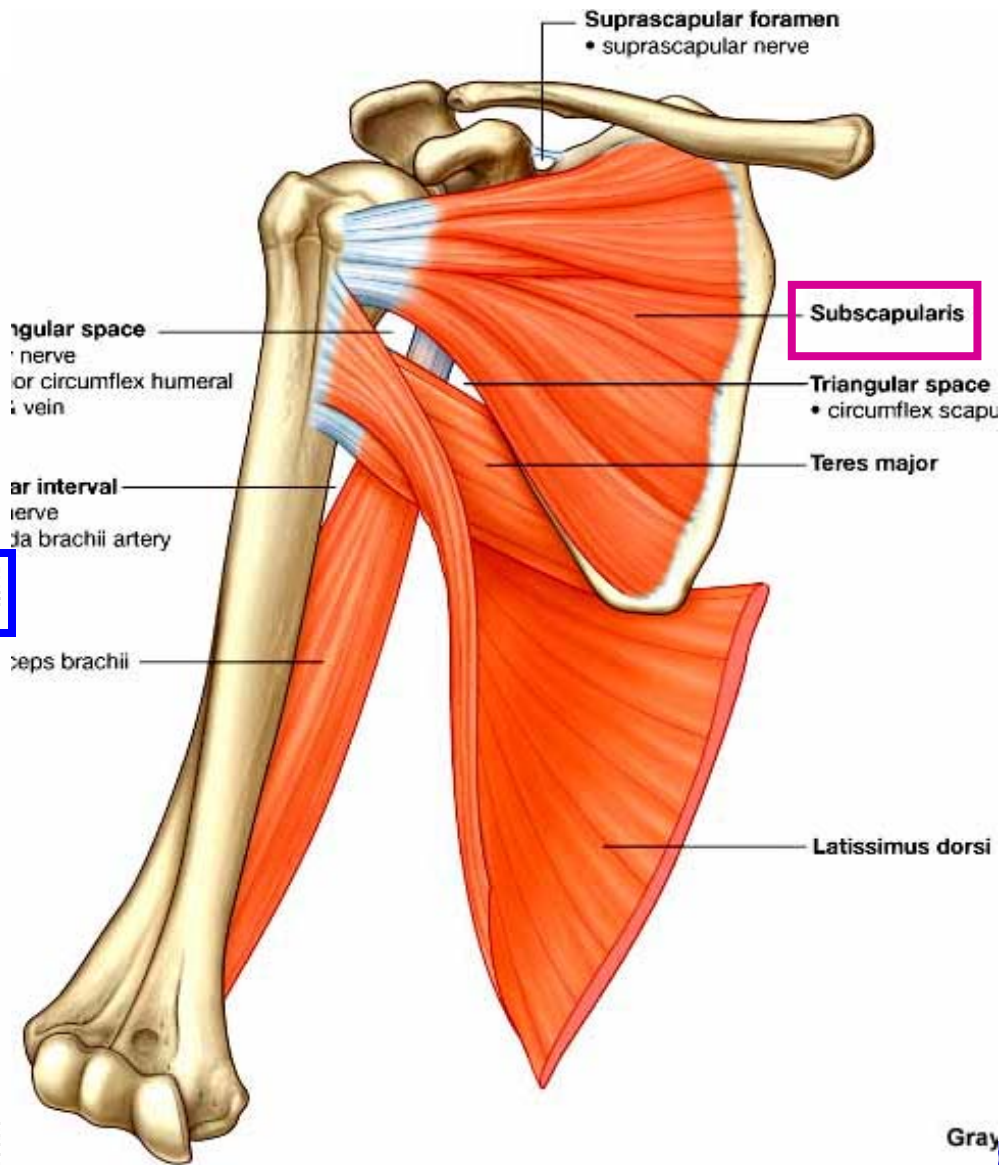
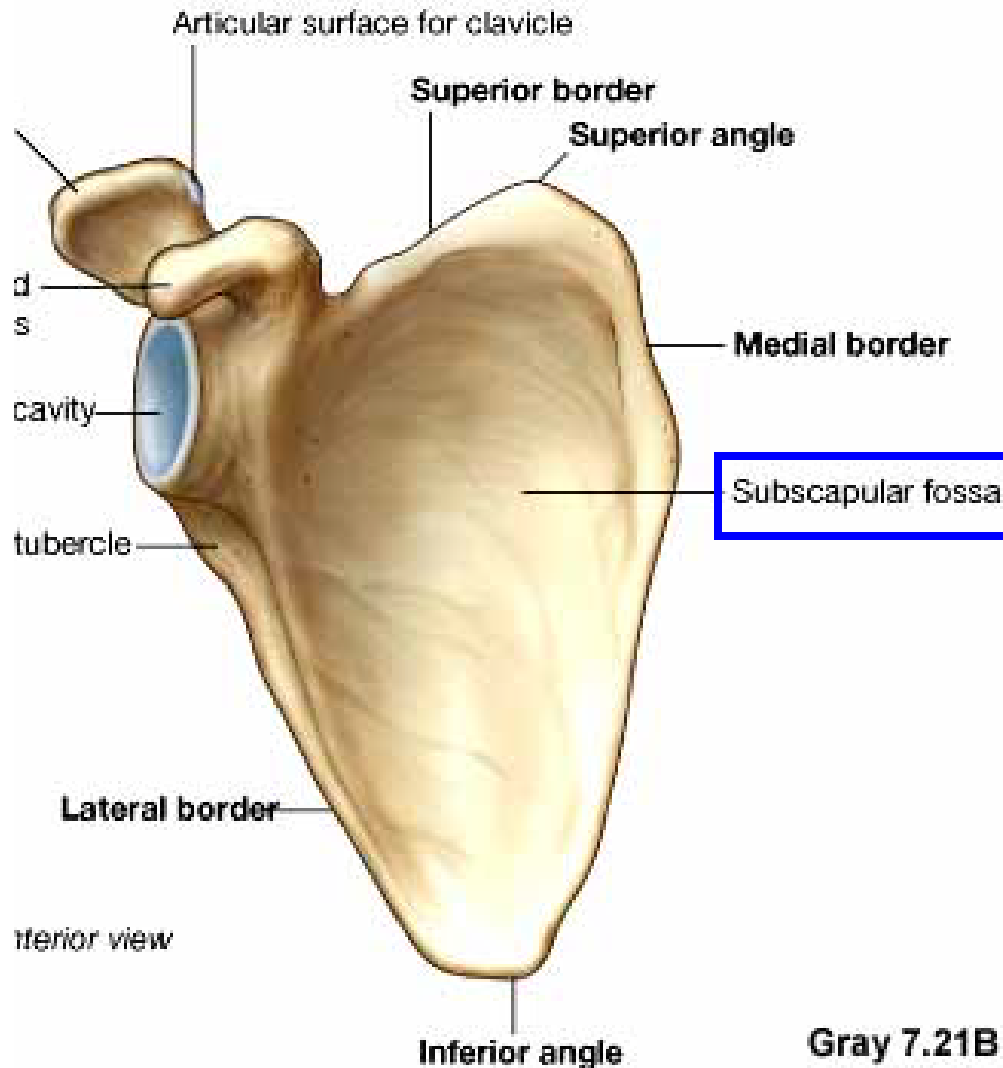
Posterior surface of Scapula, Right

- Acromion; Spine; Spinoglenoid notch
- Suprspinatous fossa, Infraspinatous fossa



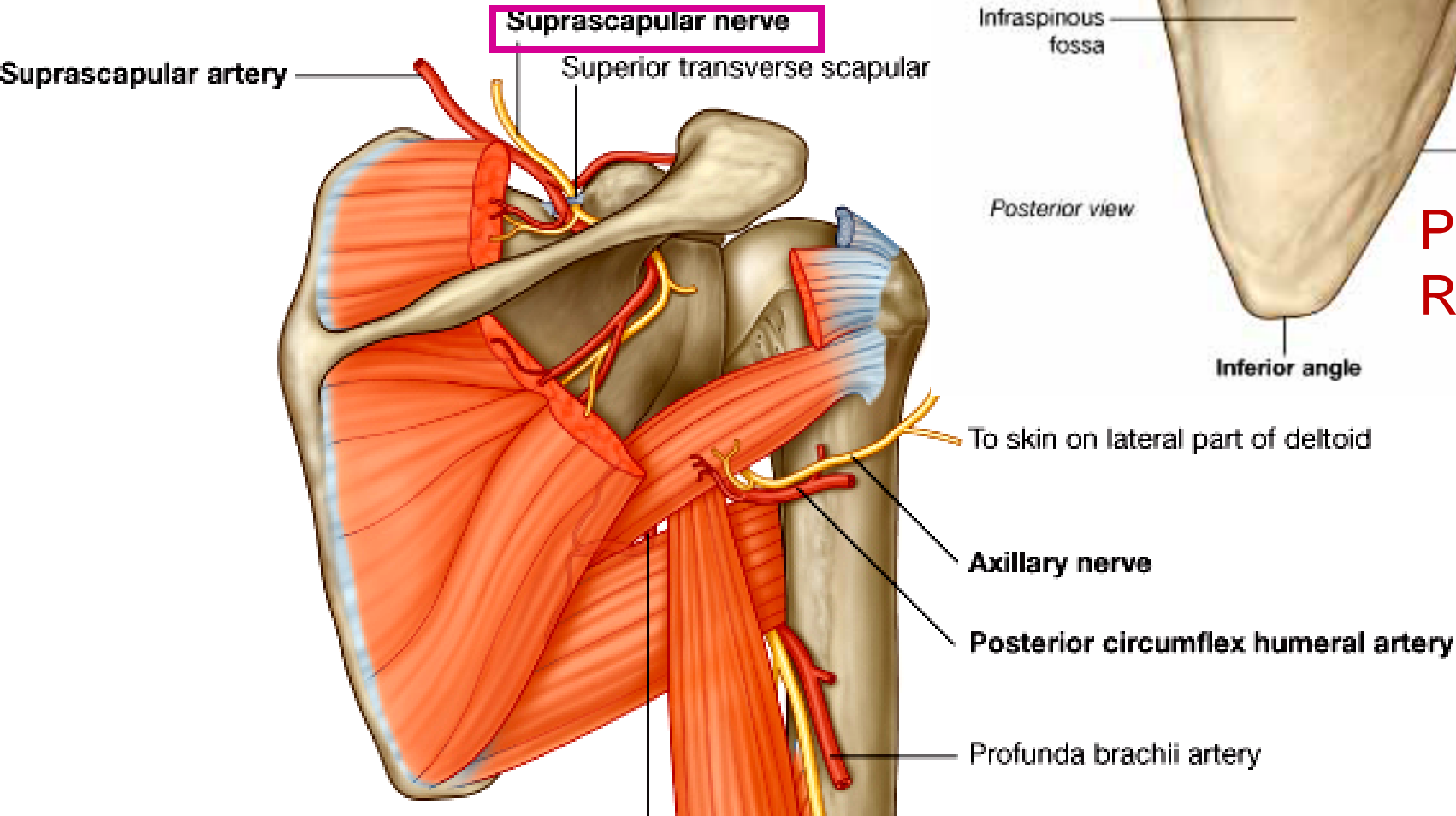
Costal (Anterior) surface of Scapula, Right

- Subscapular fossa: Shallow concave surface
- for subscapularis



Superior border

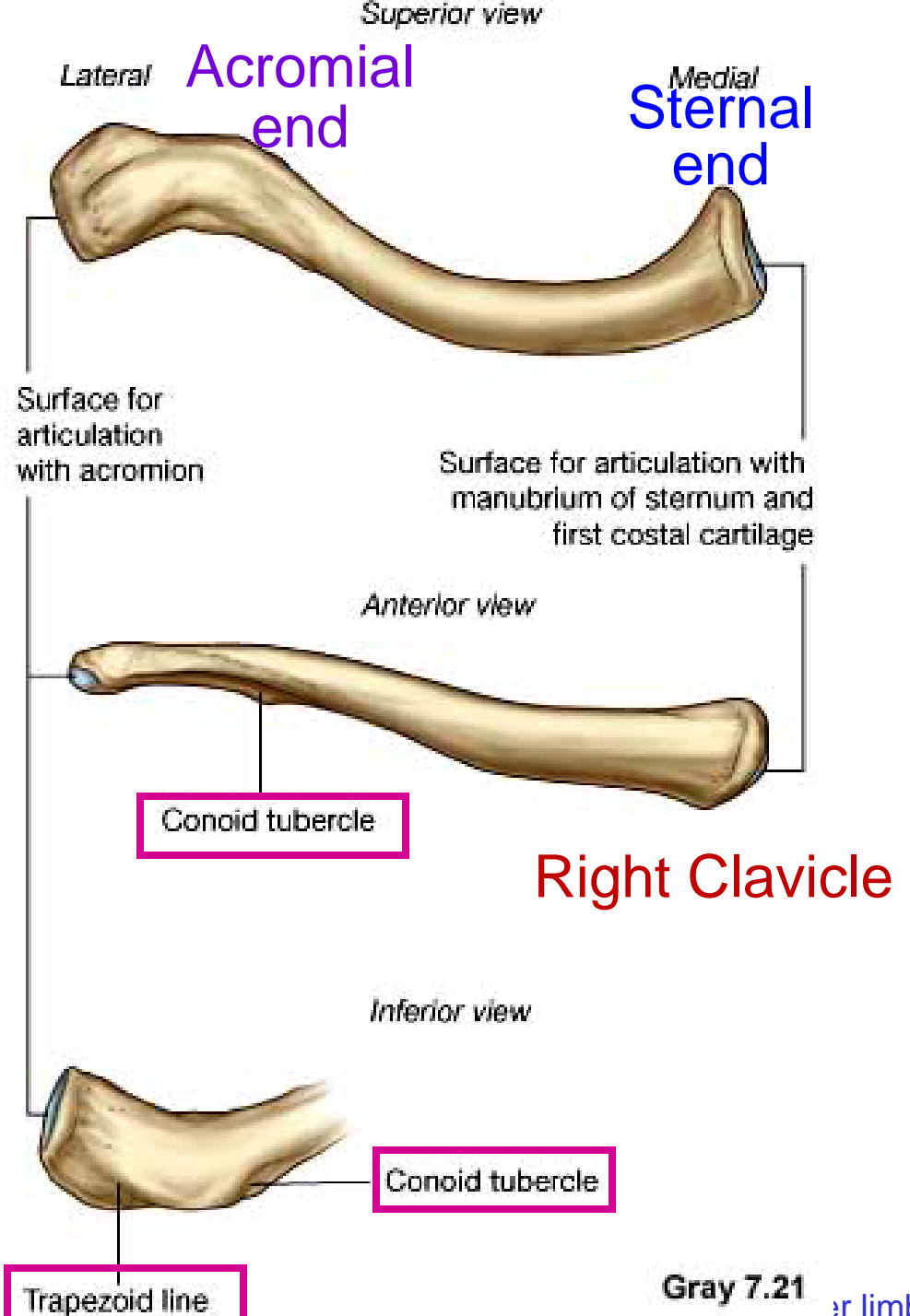
- Coracoid process
- Suprascapular notch
 - Suprascapular nerve



Posterior view:
Right Scapula

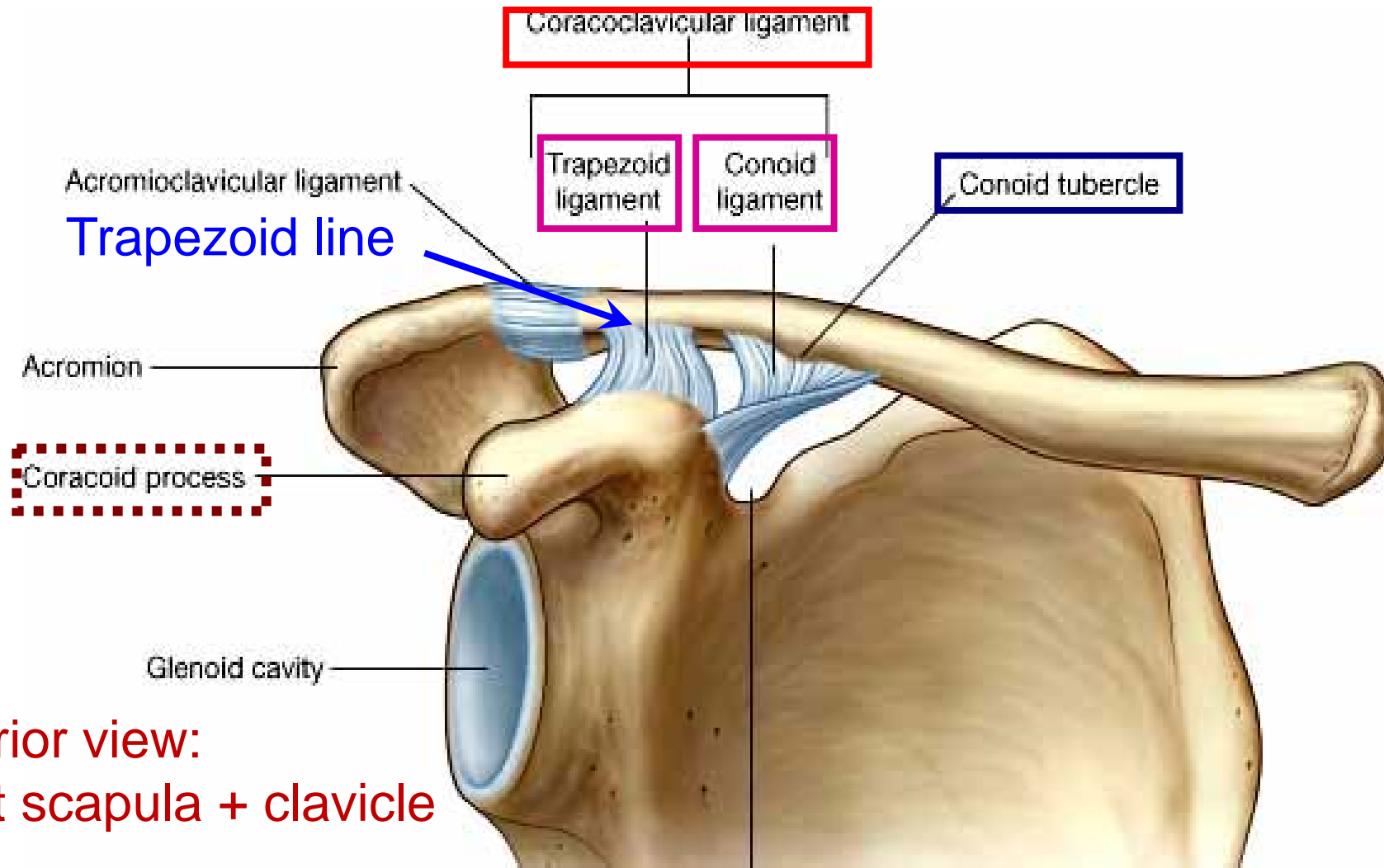
Clavicle

- S-shaped
- Acromial end: smaller, oval facet
- Sternal end: larger, quadrangular facet, with manubrium, 1st rib
- Conoid tubercle
- Trapezoid line



Clavicle

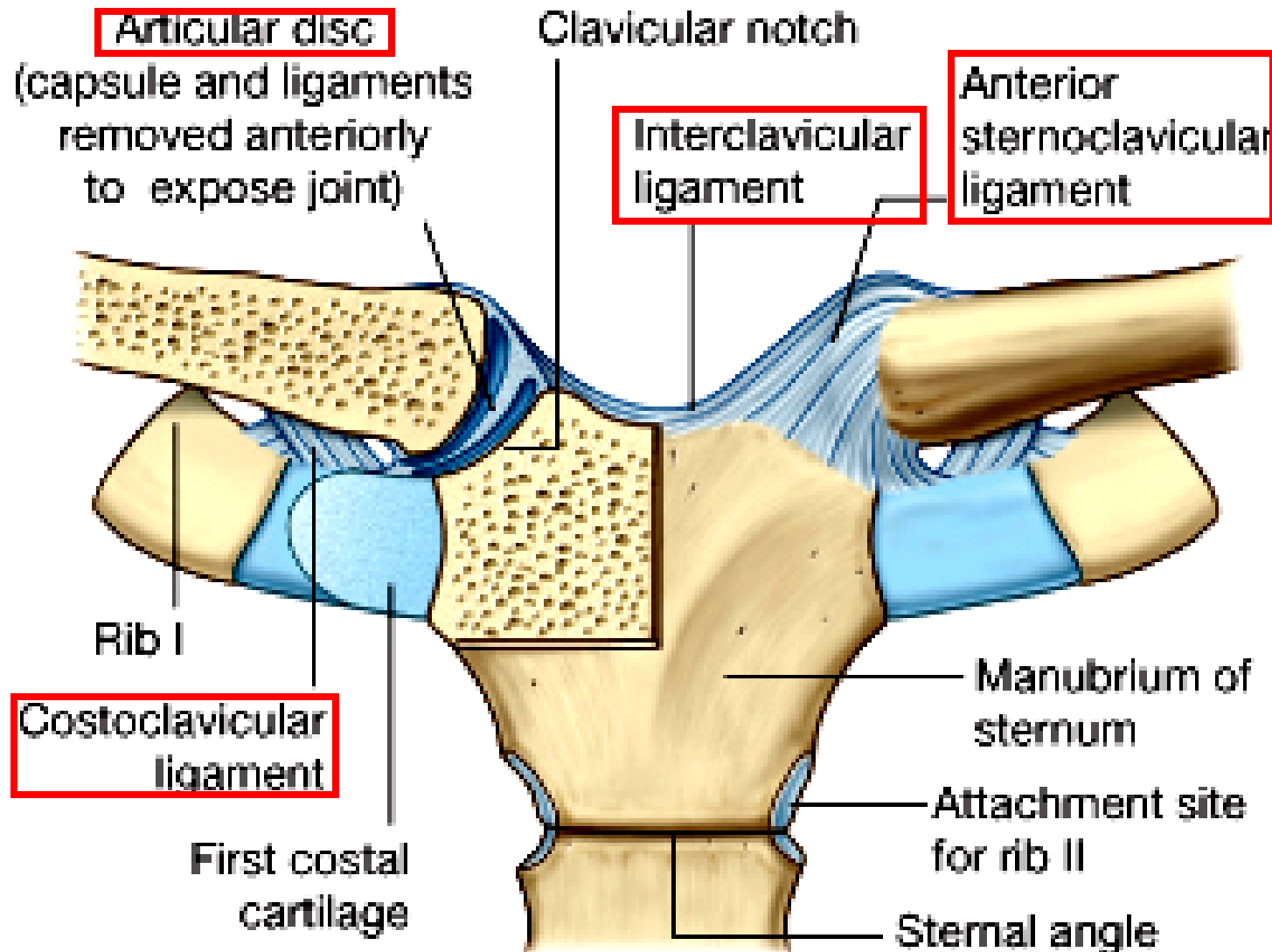
- Conoid tubercle: inferior surface, lateral 1/3; conoid ligament
- Trapezoid line: lateral roughing; trapezoid ligament
- Coracoclavicular ligament = conoid + trapezoid



Anterior view:
Right scapula + clavicle

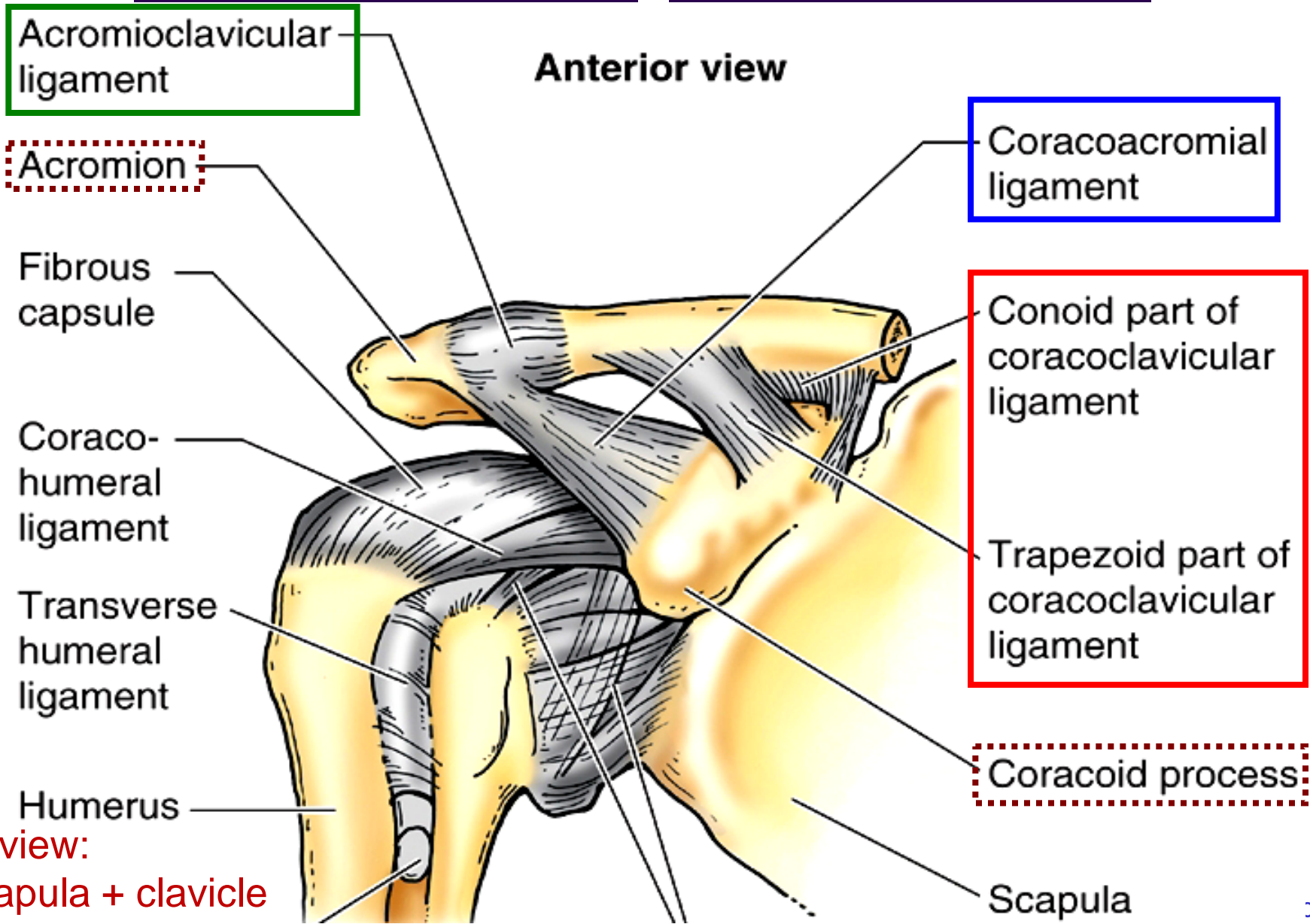
Sternoclavicular joint

- ant. & post. sternoclavicular lig.; costoclavicular lig., interclavicular lig.

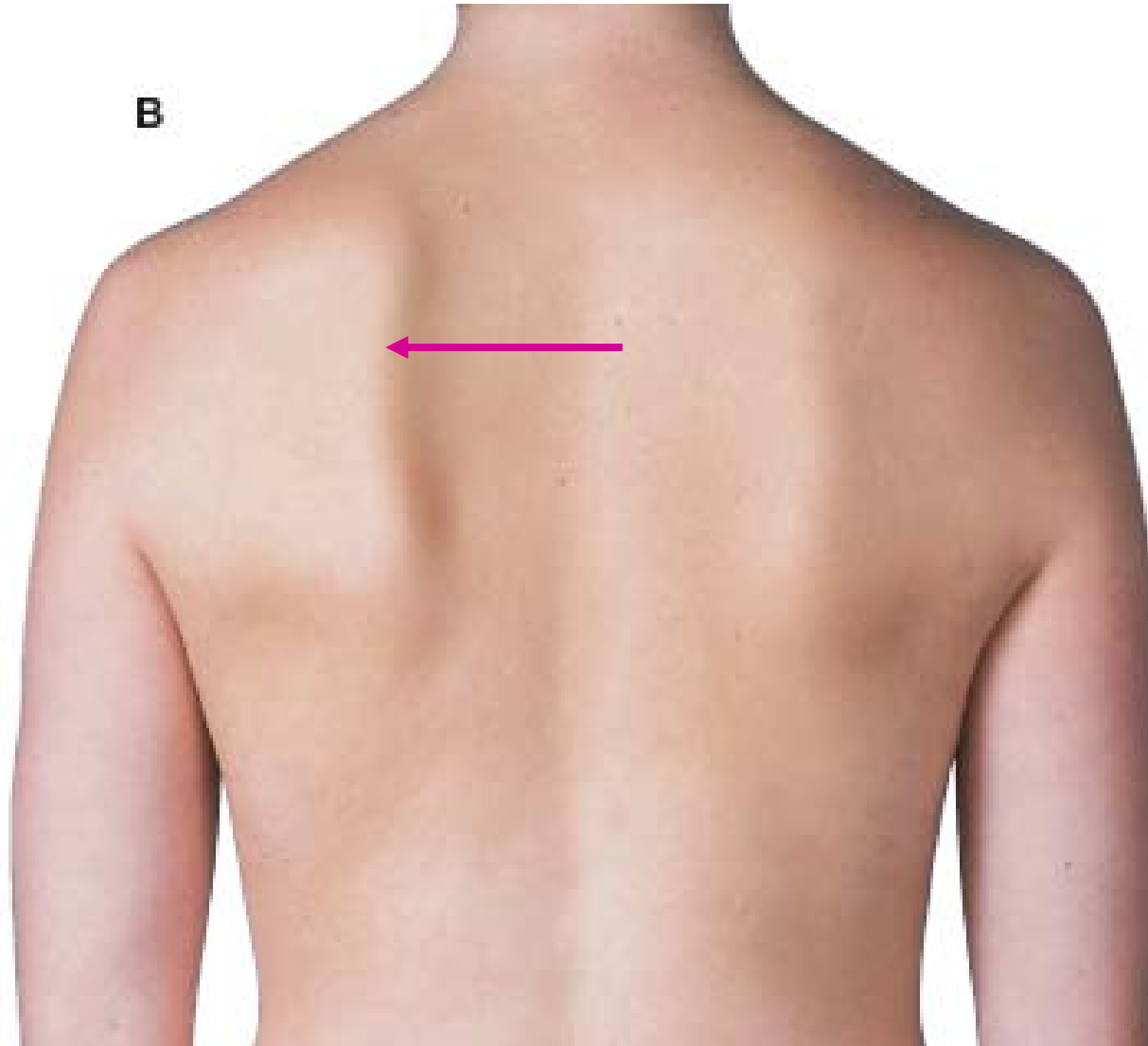


Acromioclavicular joint

- Coracoclavicular lig., Coracoacromial lig.



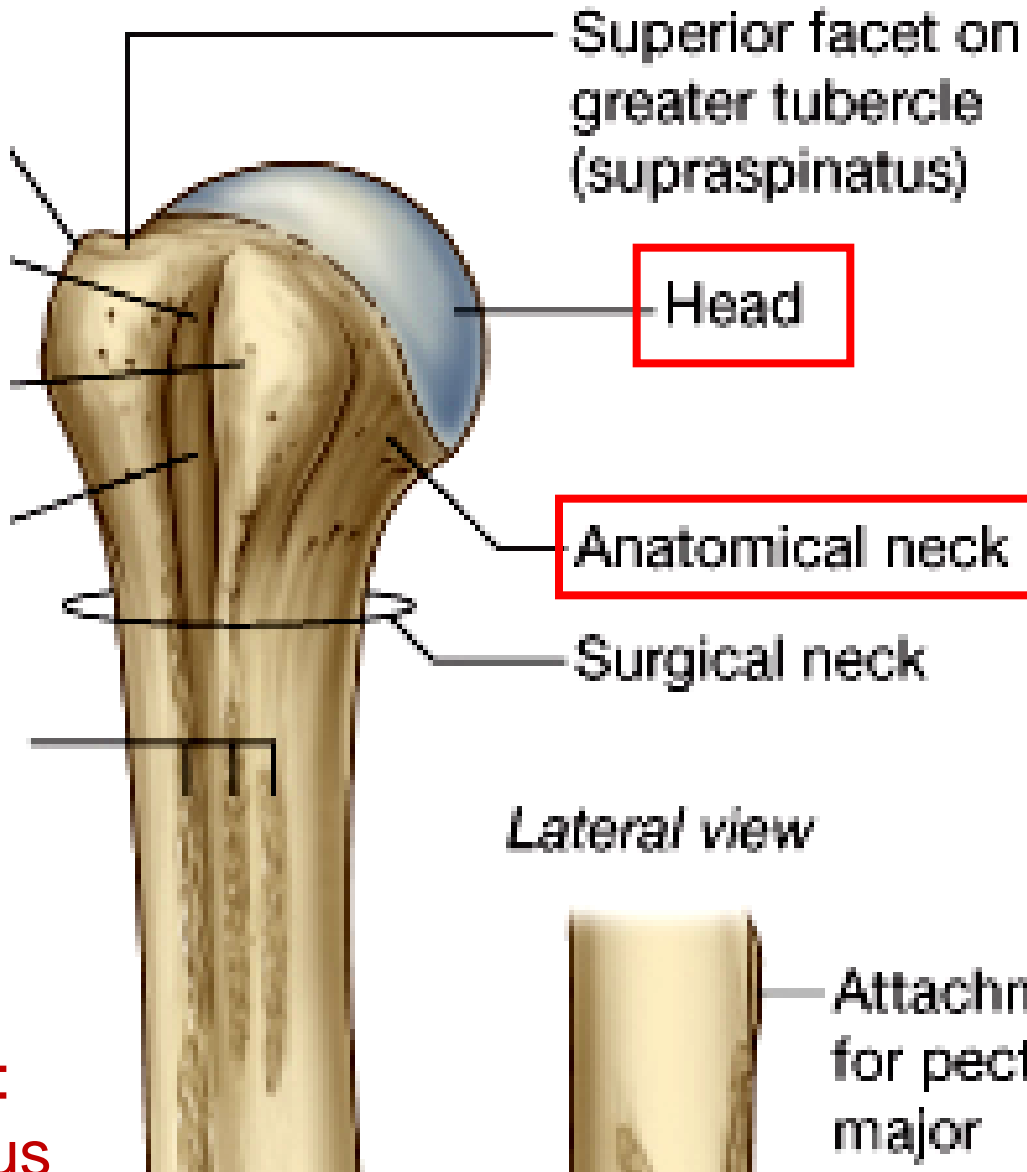
Surface anatomy of scapula



Humerus: proximal end

- Head
 - Half-spherical; glenoid cavity
- Anatomical neck
 - Narrow constriction below head

Anterior view

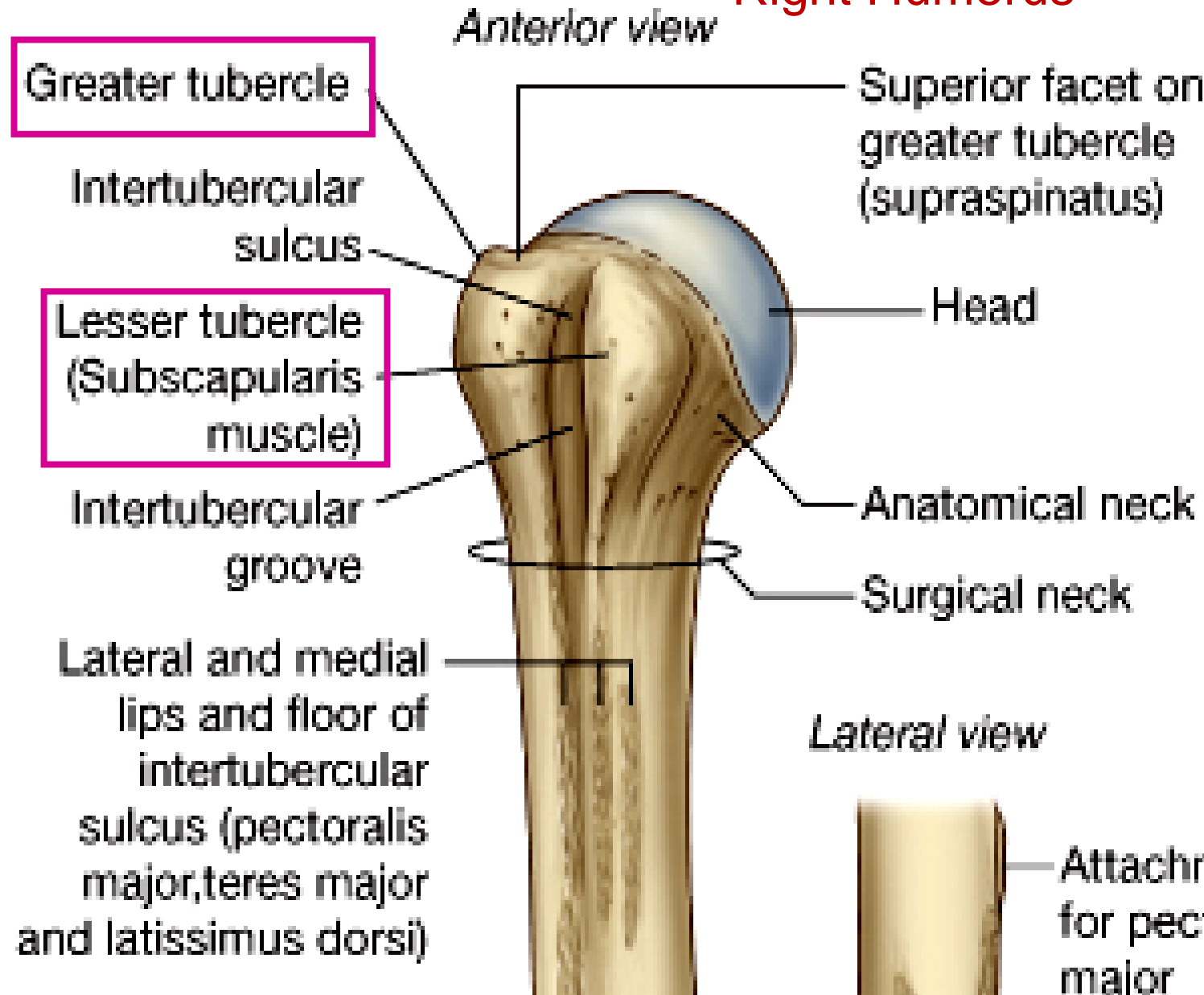


Anterior view:
Right Humerus

Humerus: proximal end

- Greater tubercle
 - Supraspinatus
 - Infraspinatus
 - Teres minor
- Lesser tubercle
 - subscapularis

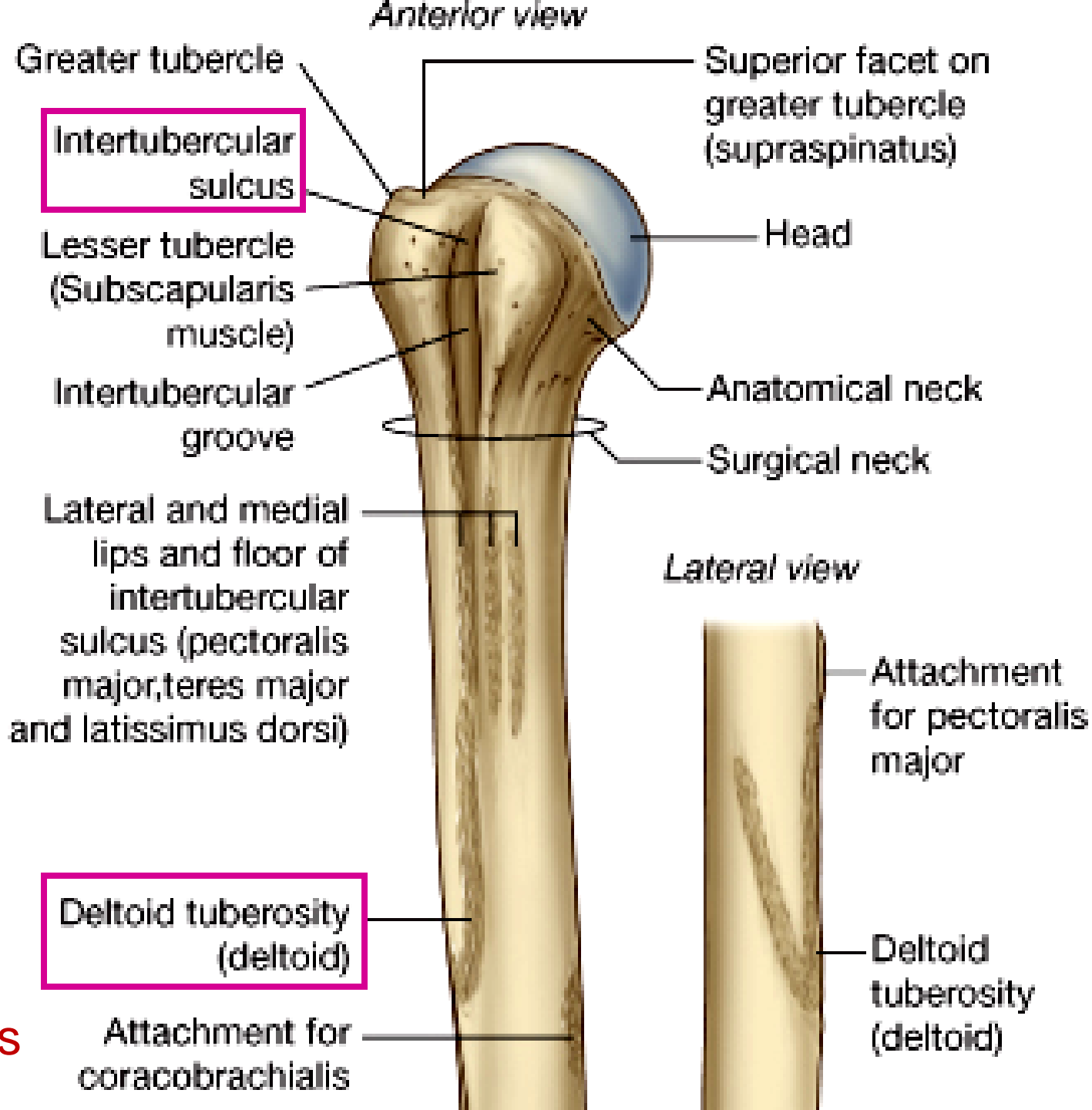
Anterior view:
Right Humerus



Humerus: proximal end

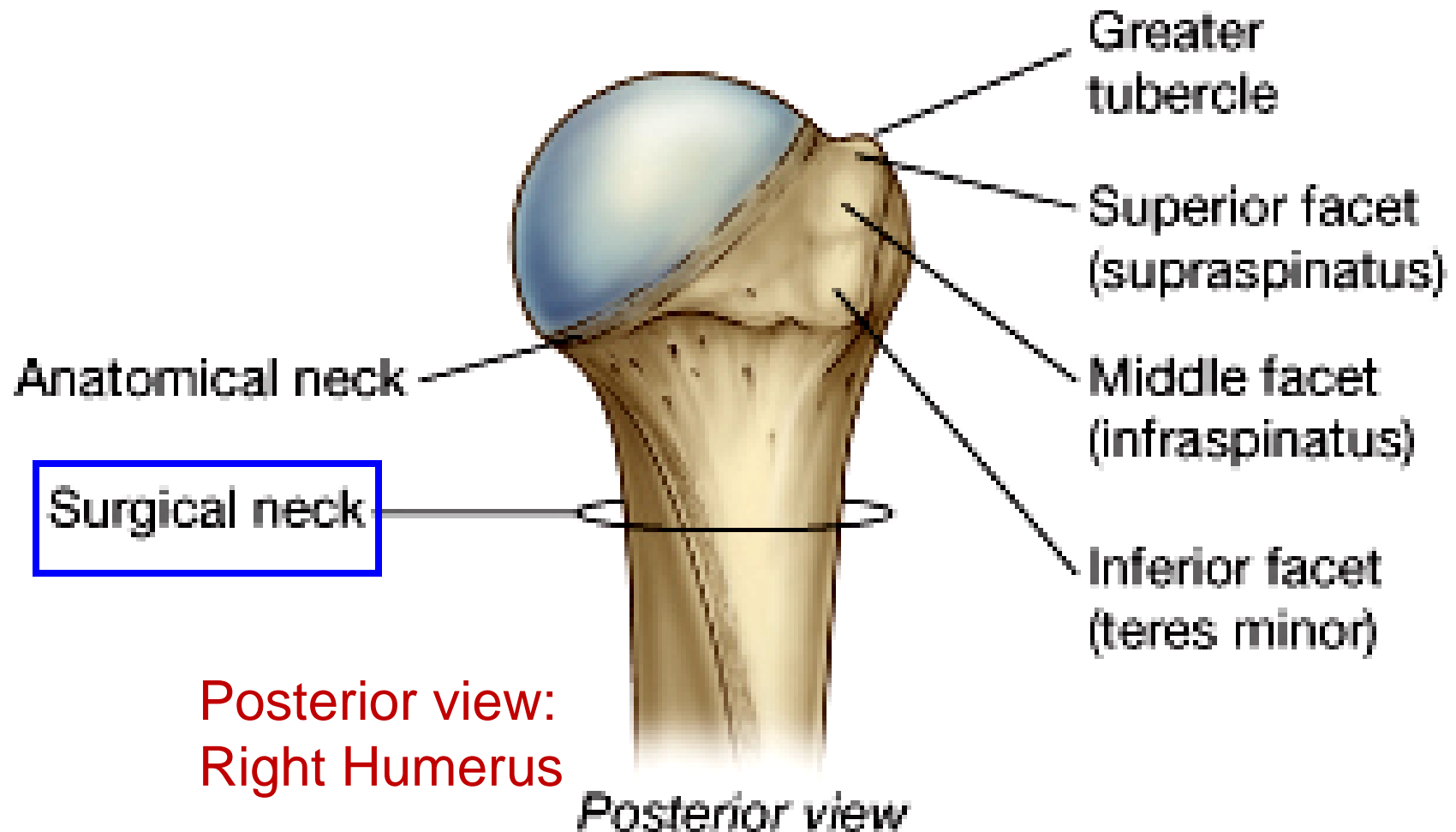
- Intertubercular sulcus (bicipital groove)
 - Long head of biceps brachii
- Deltoid tuberosity
 - lateral surface
 - Deltoid

Anterior view:
Right Humerus

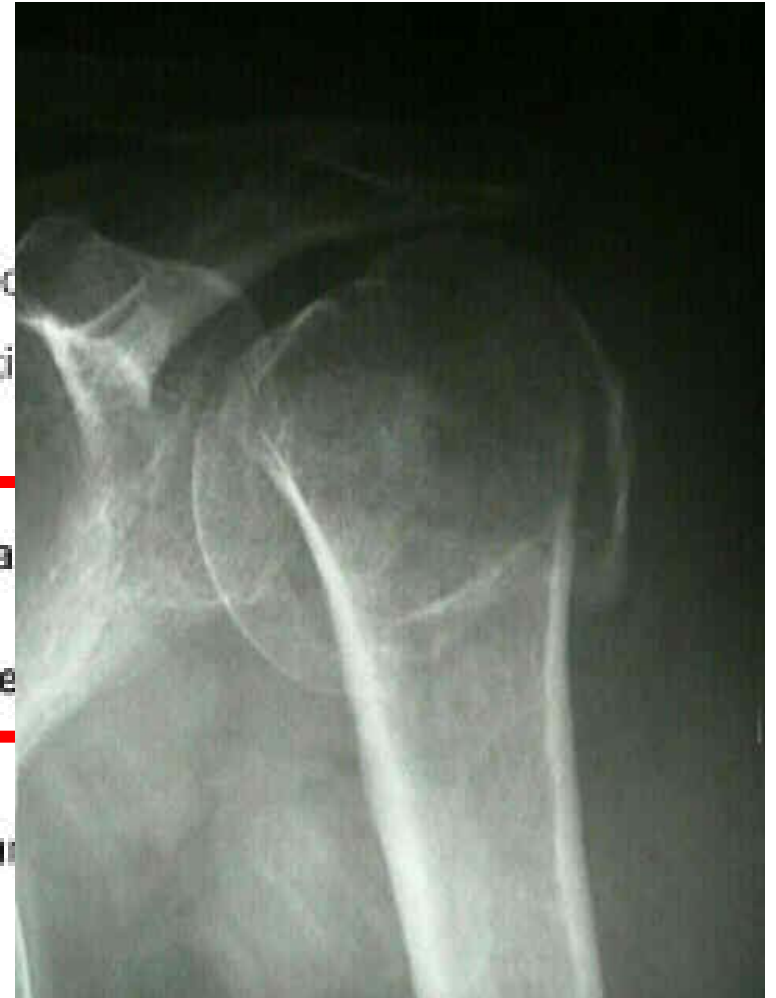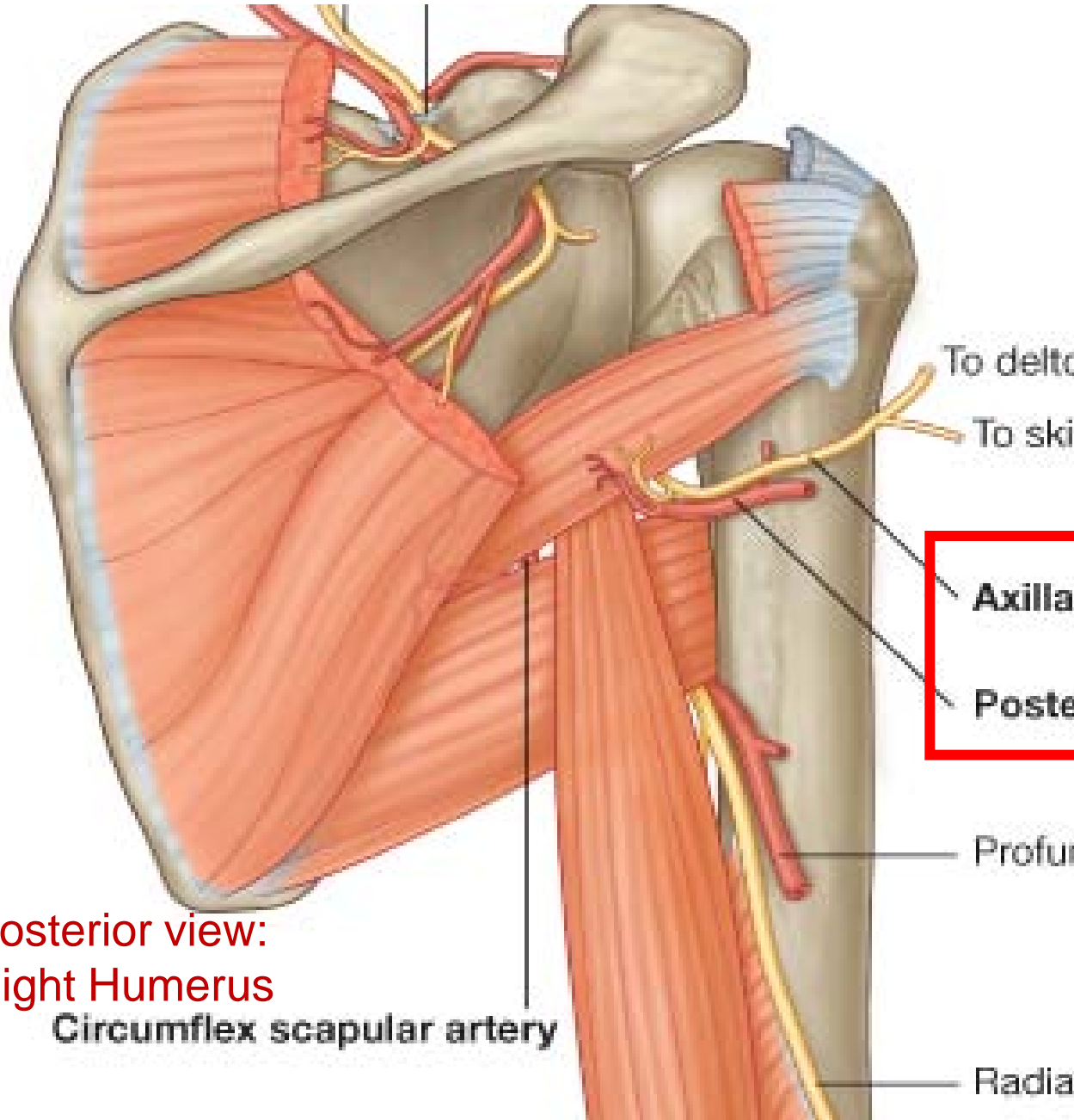


Neck: anatomical vs. surgical

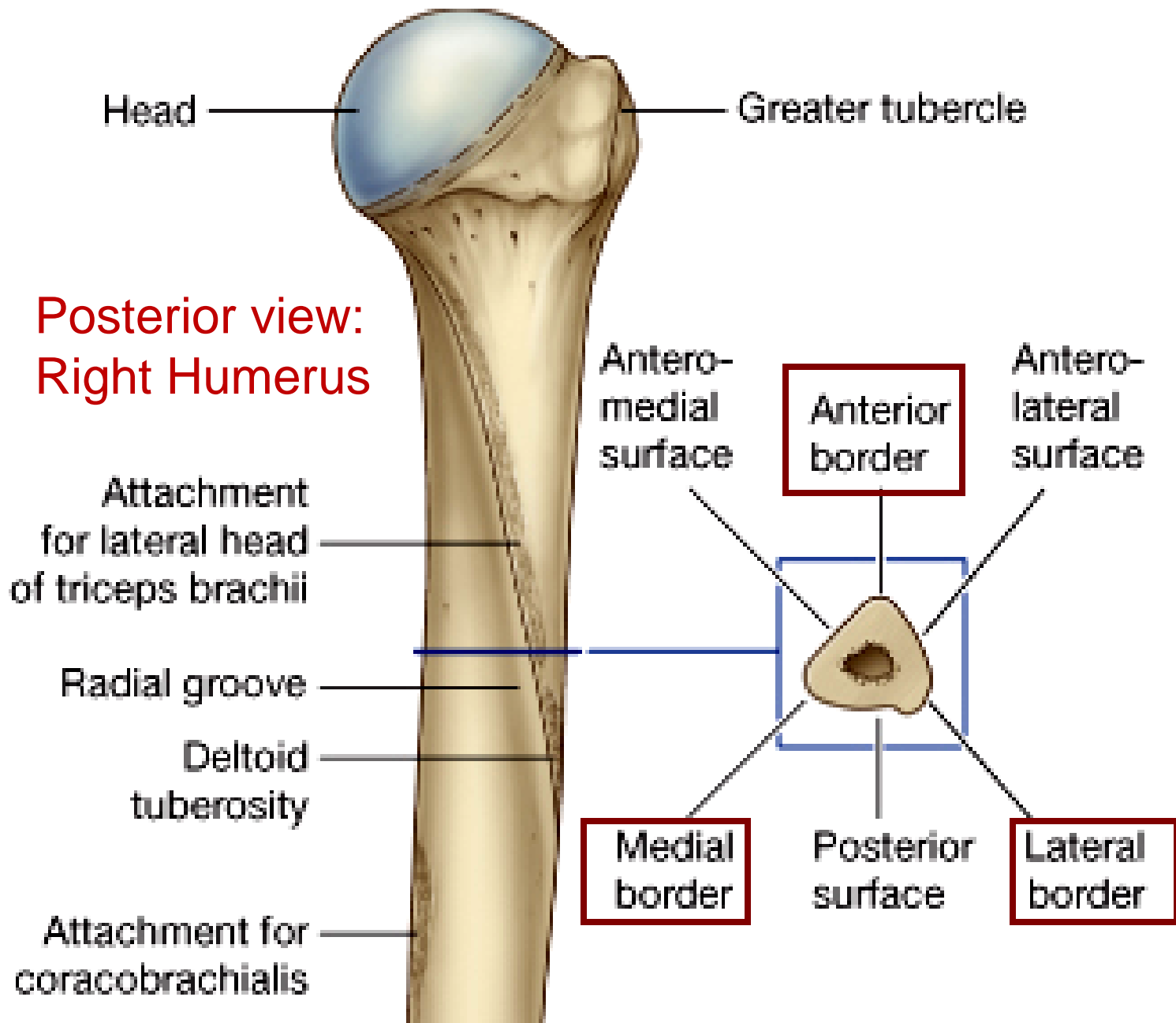
- Surgical neck: between expanded part and narrow shaft; injury upon fracture; passing of axillary nerve and post. circumferentia humeral artery



Surgical neck of humerus: axillary n & circumf. a



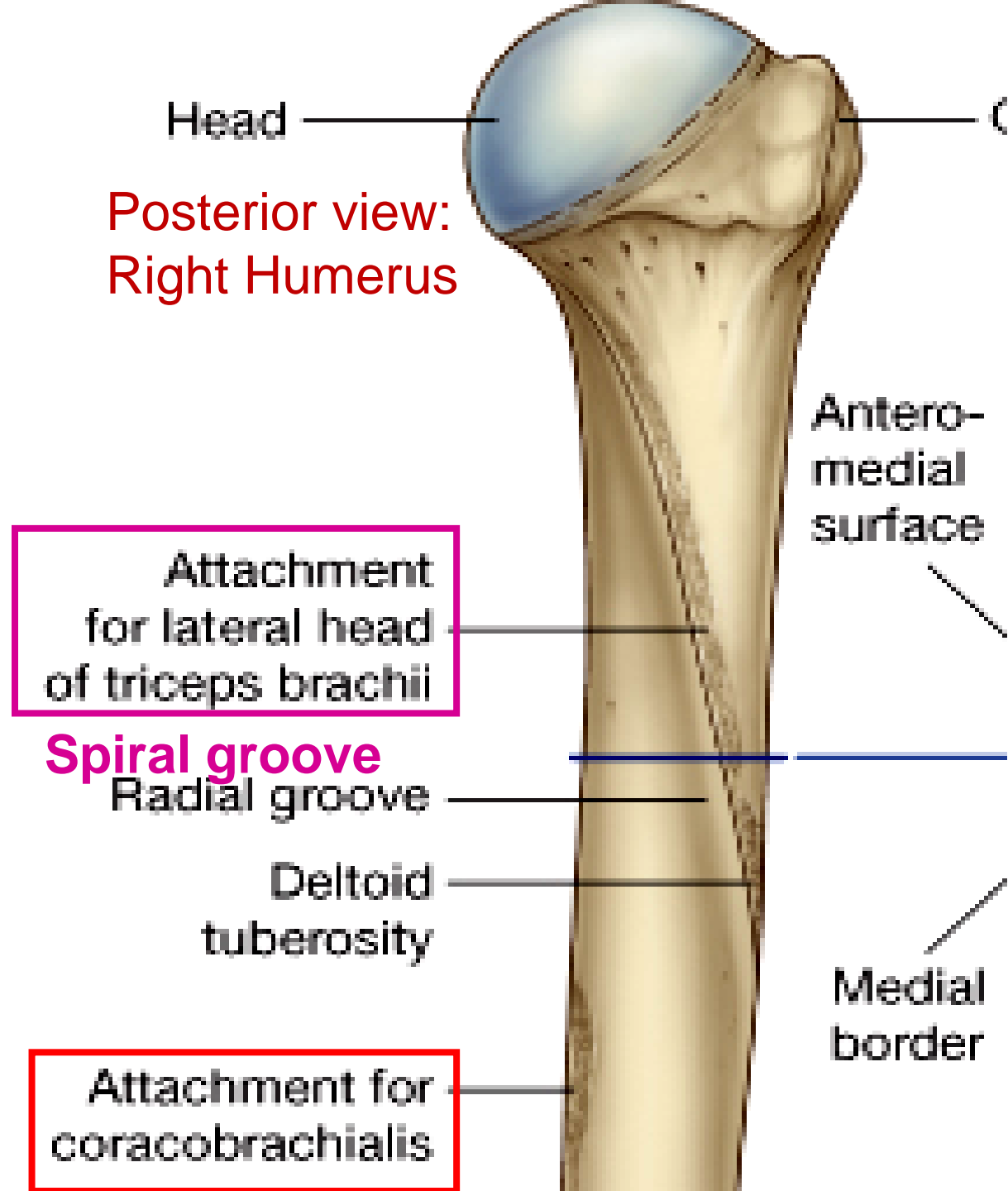
Humerus: Shaft and distal end



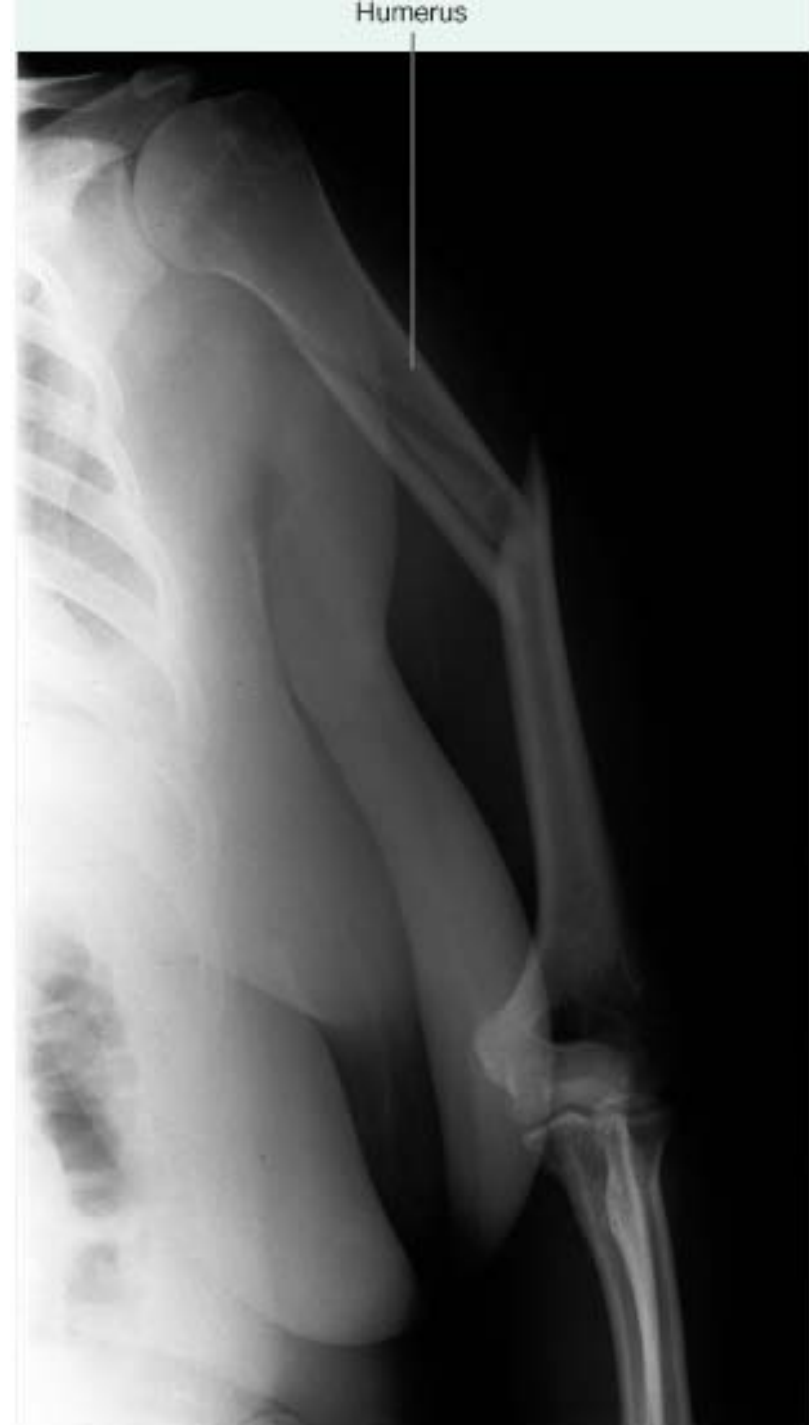- Borders
 - Anterior, lateral, medial
- Surfaces
 - Anterolateral, anteromedial, posterior surfaces

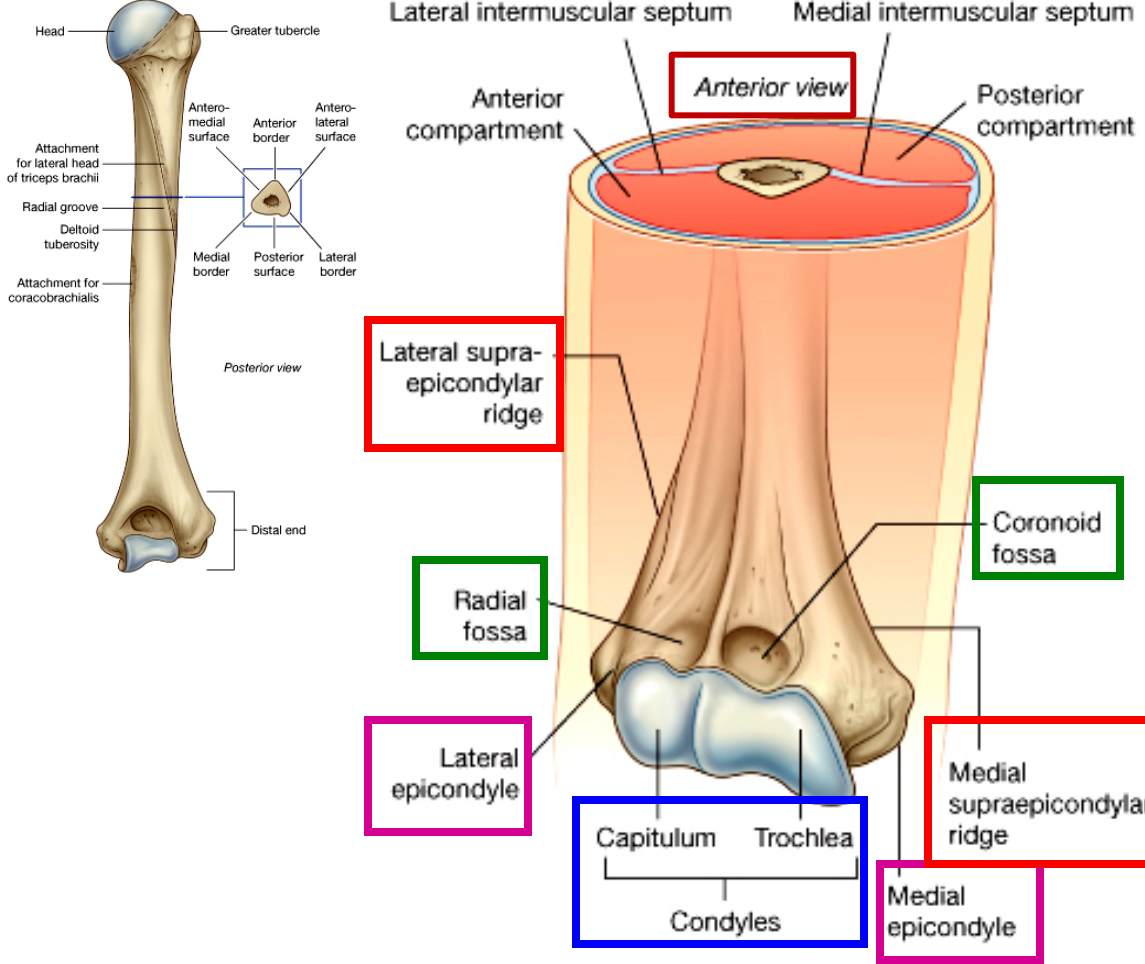
Humerus: posterior surface

- A diagonal line from surgical neck to deltoid tuberosity; lateral head of triceps brachii
- **Spiral groove:** radial nerve, profunda brachial artery
- Middle part with coracobrachialis



Fracture of Humerus

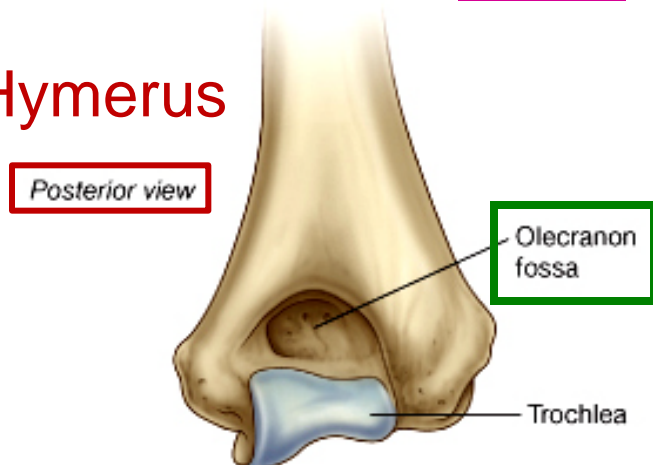




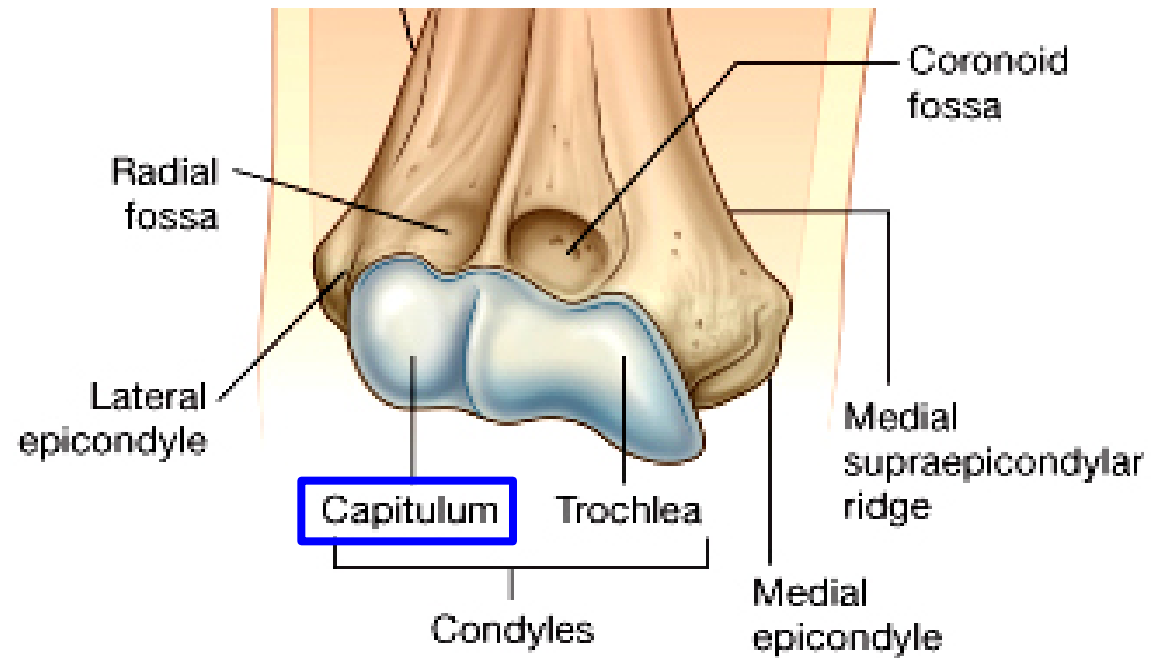
Humerus: Distal end

- 1 condyle
 - Capitulum, Trochlea
- 2 epicondyles
 - Medial, Lateral
- 2 supracondylar ridge
 - Medial, Lateral
- 3 fossa
 - Coronoid, Radial, Olecranon

Right Humerus

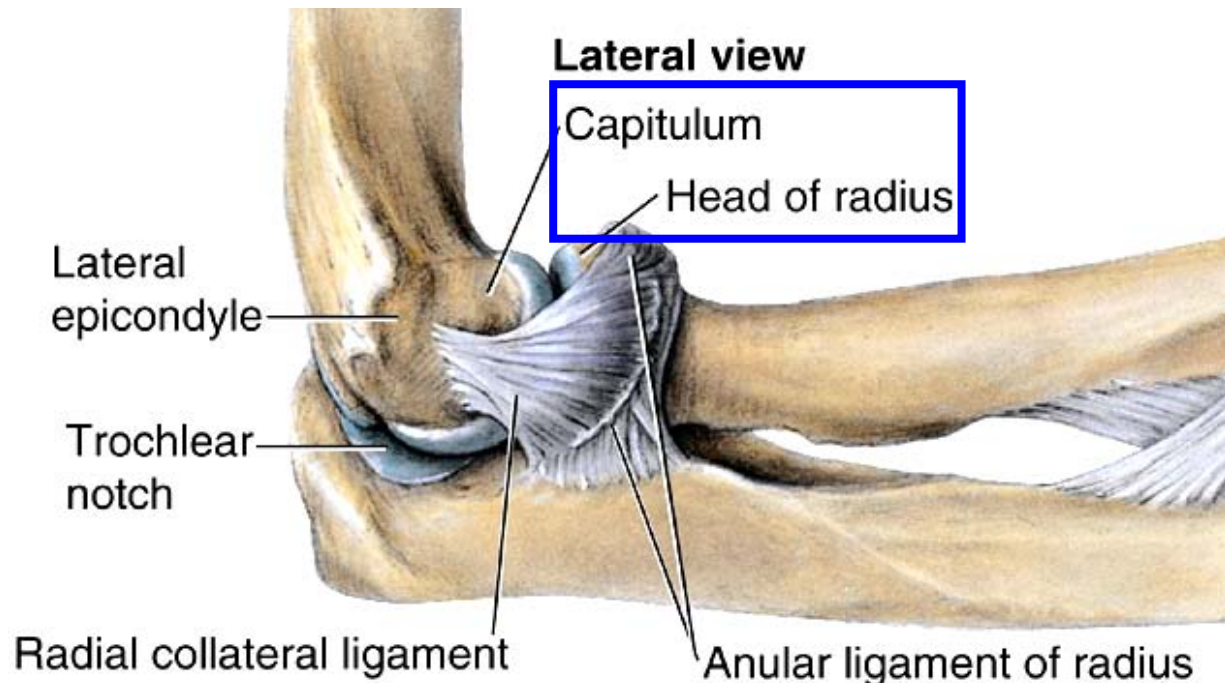


Anterior view: Right Humerus



Capitulum of humerus

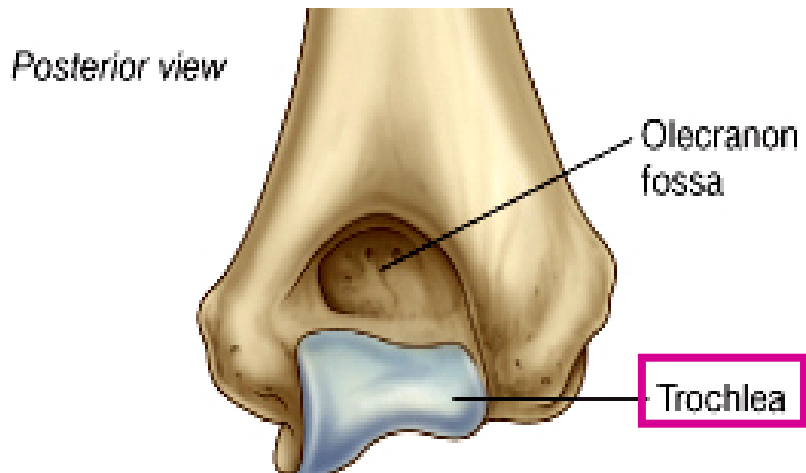
- Capitulum
 - Lateral, hemispherical
 - with radius
 - Not visible posteriorly



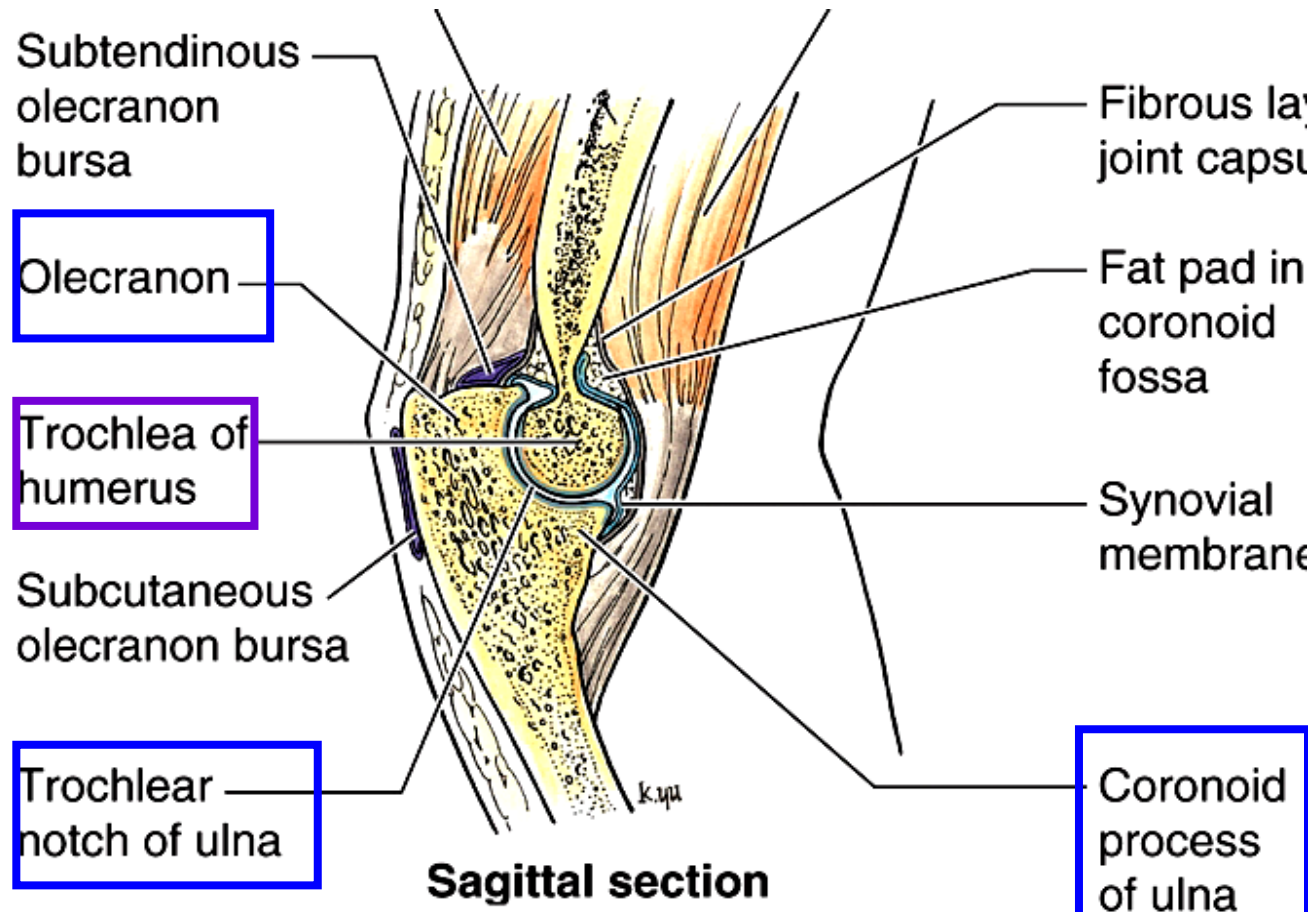
Medial view: Right humerus + ulna / radius

Trochlea of humerus

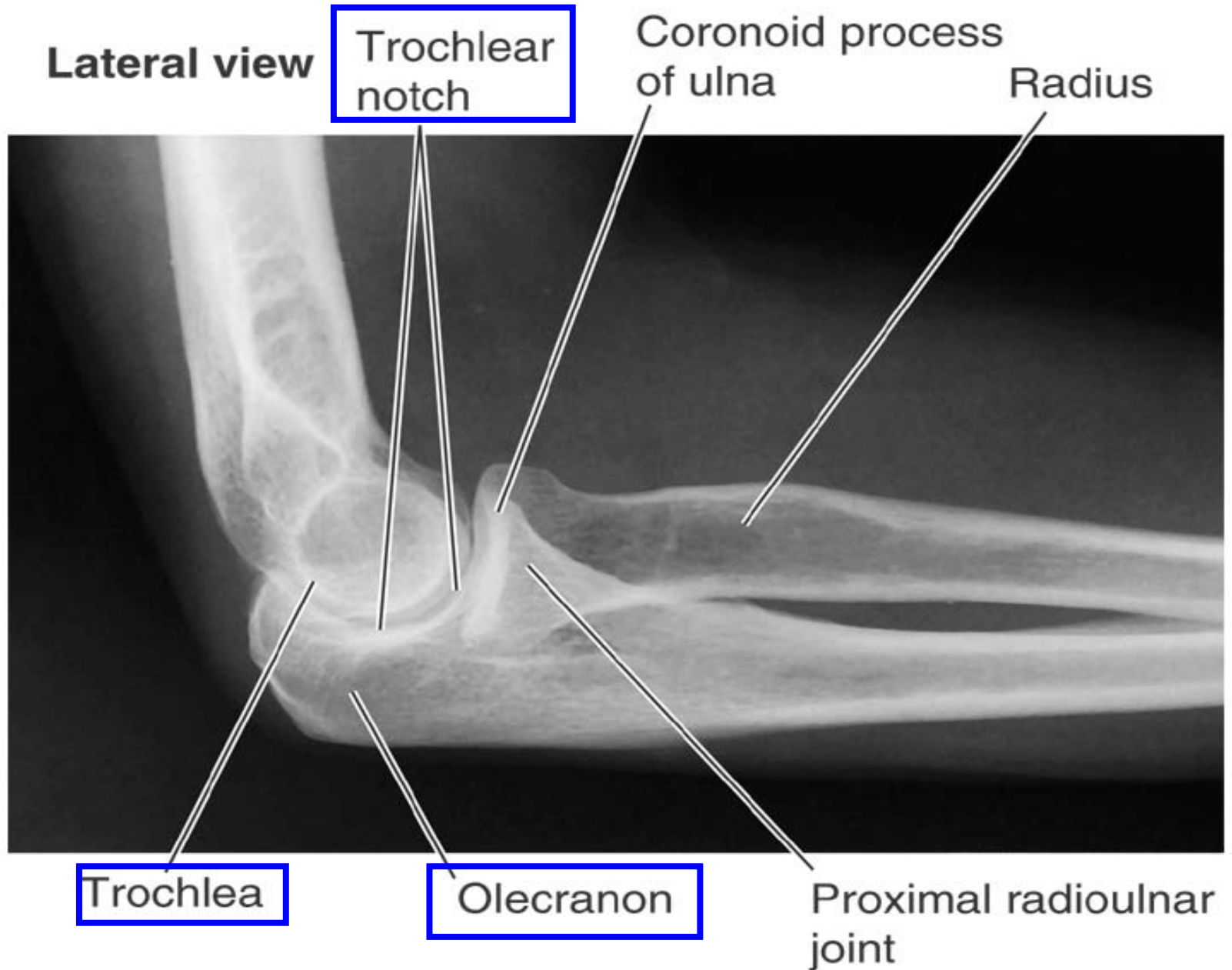
- Trochlea
 - Medial one, “pulley”
 - with ulnar (trochlea notch)
 - Extending posteriorly



Posterior view: Right Humerus

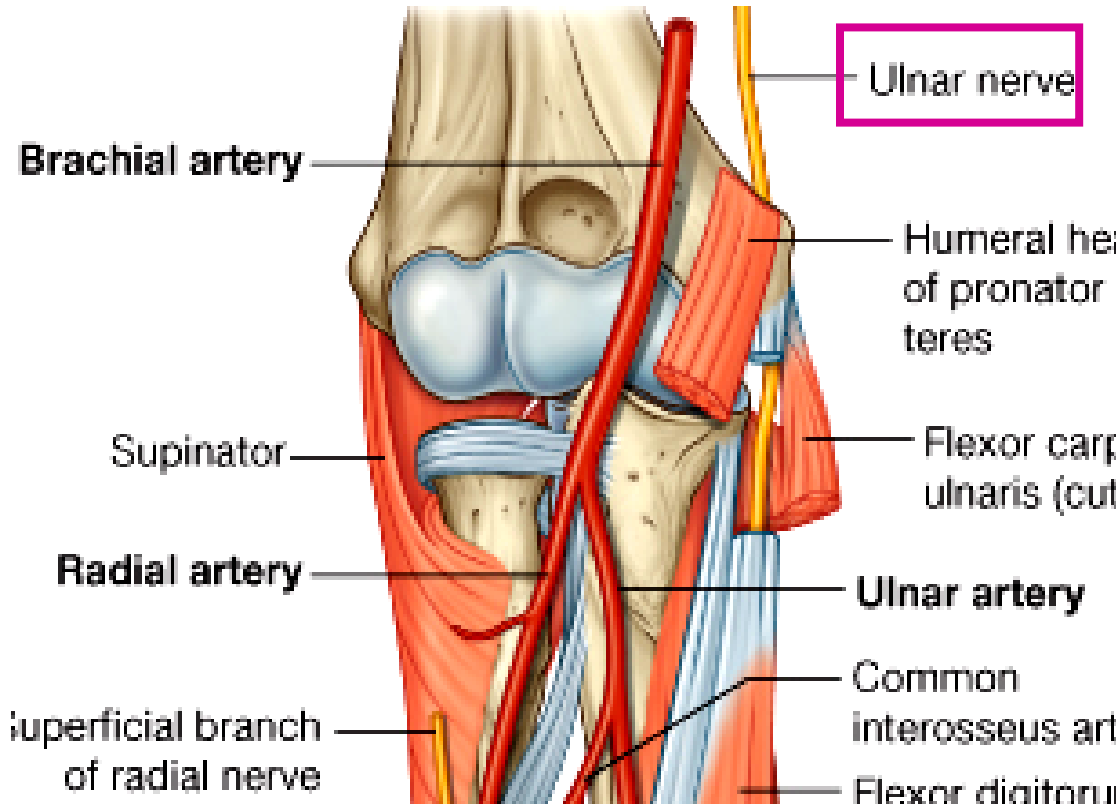
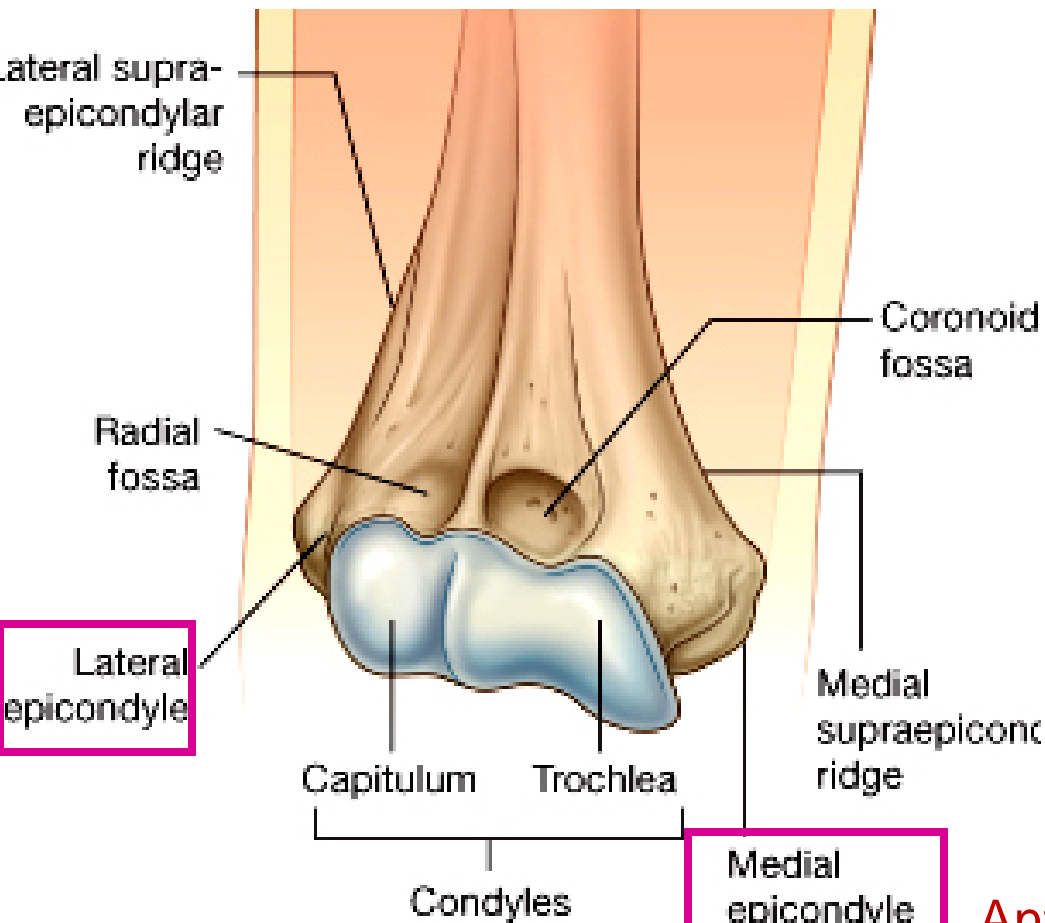


Trochlea of humerus



Epicondyles of humerus

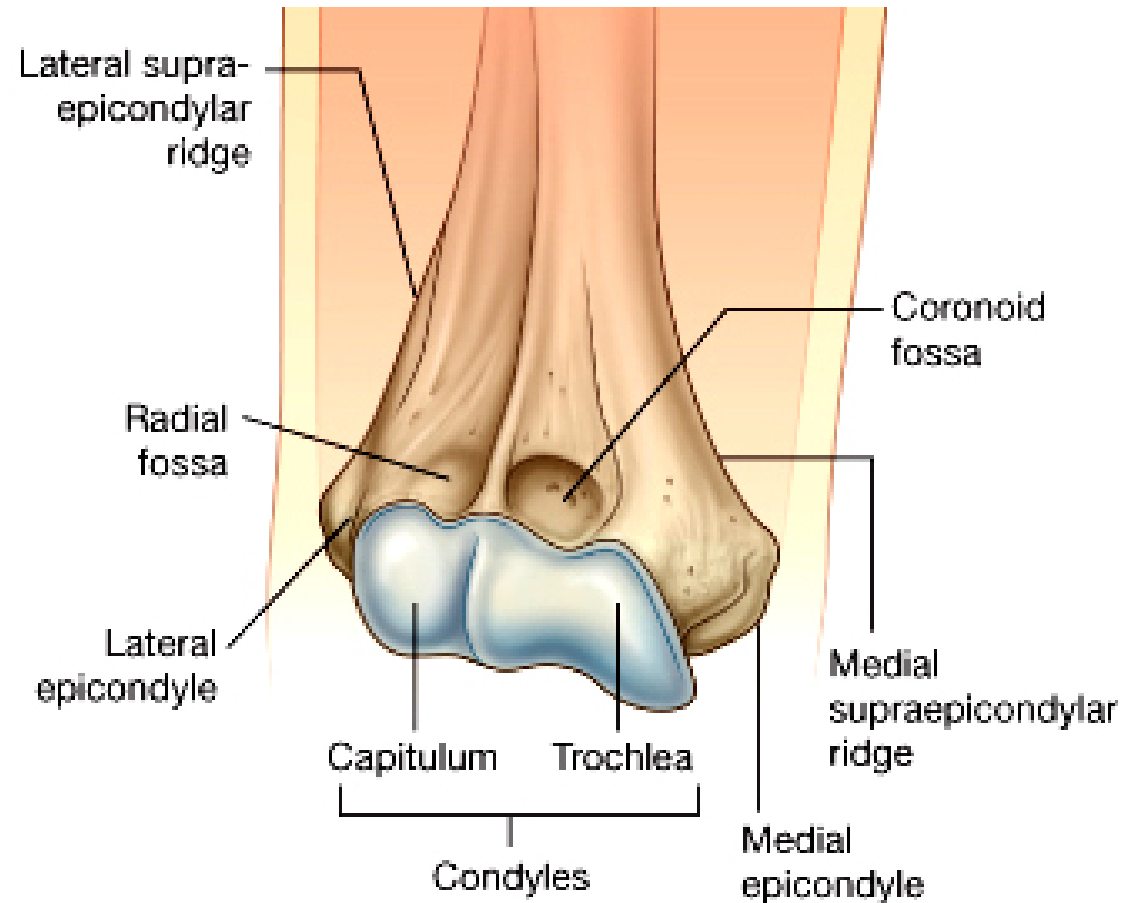
- Medial epicondyle: Palpable on medial side of elbow
 - ulnar nerve around posterior surface
- Lateral epicondyle: Palpable on lateral side of elbow



Anterior view: Right Humerus

Humerus: Fossa-1

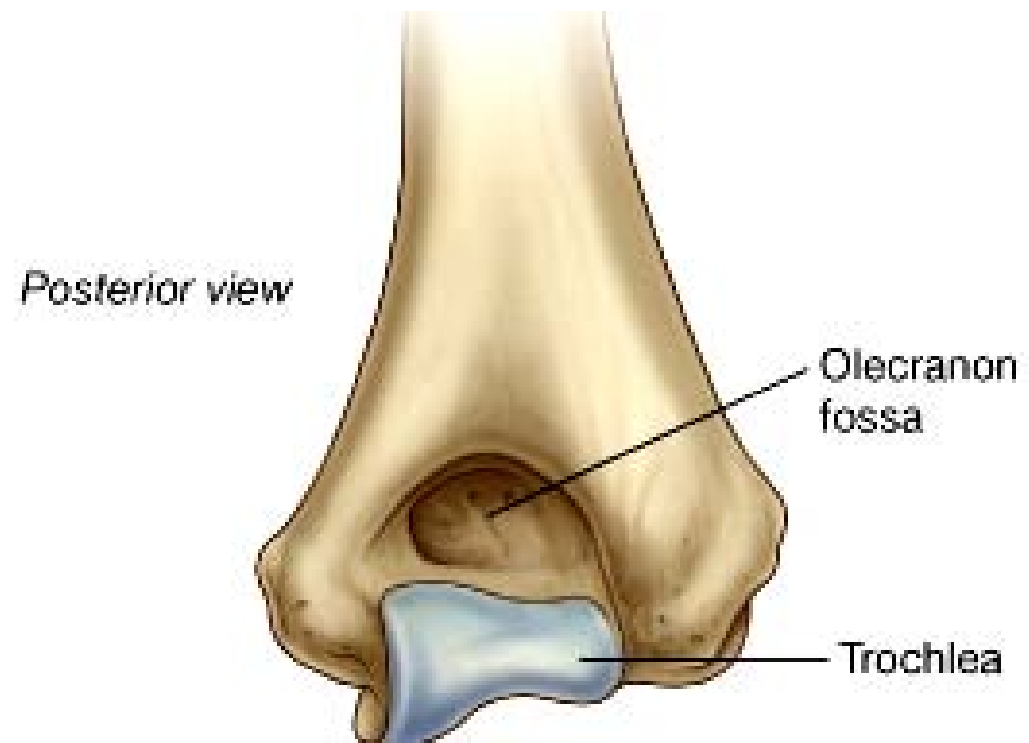- Anterior
 - Radial fossa: above capitulum
 - Coronoid fossa: above trochlea



Anterior view: Right Humerus

Humerus: Fossa-2

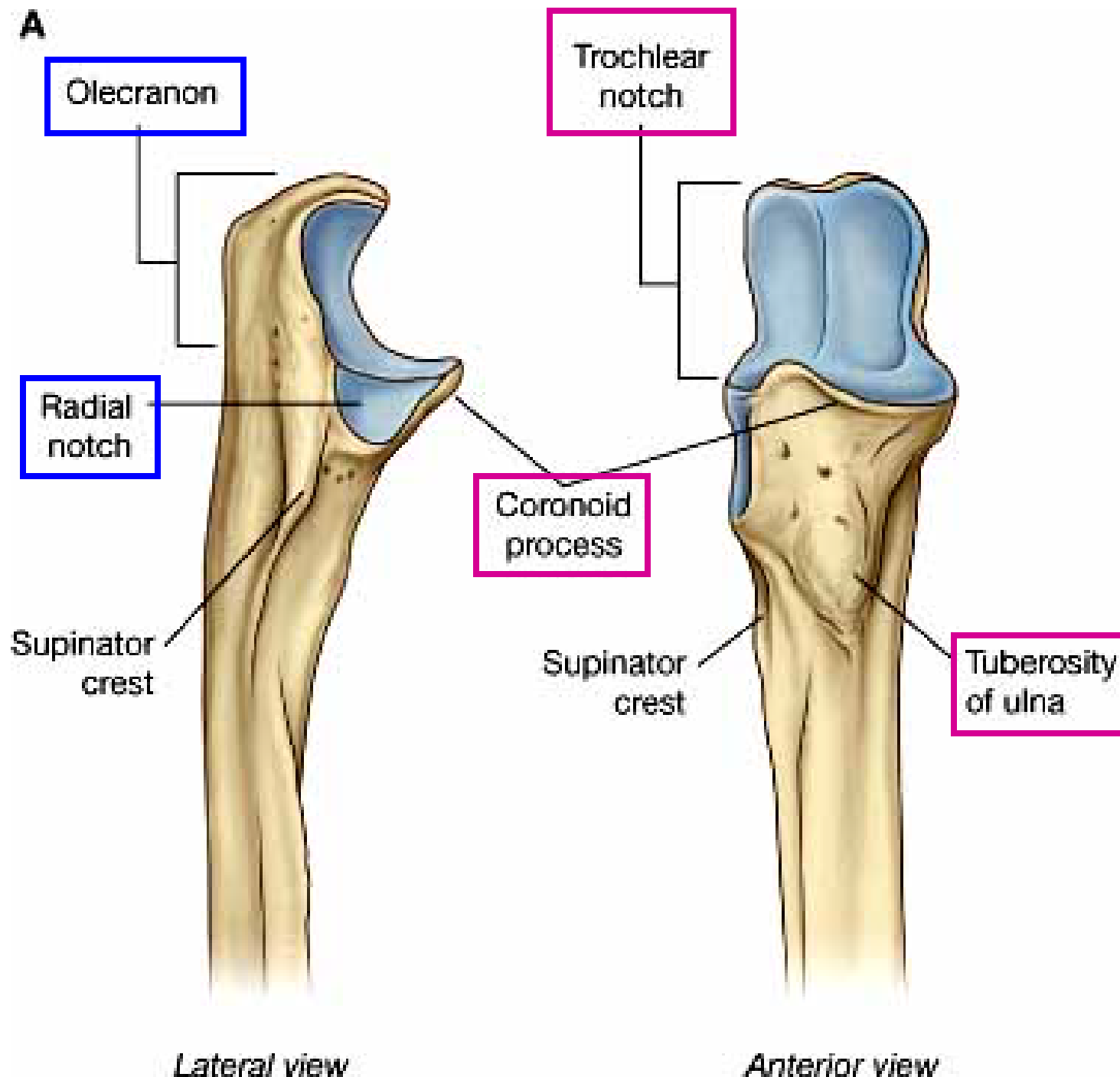
- Posterior
 - Olecranon fossa: the largest

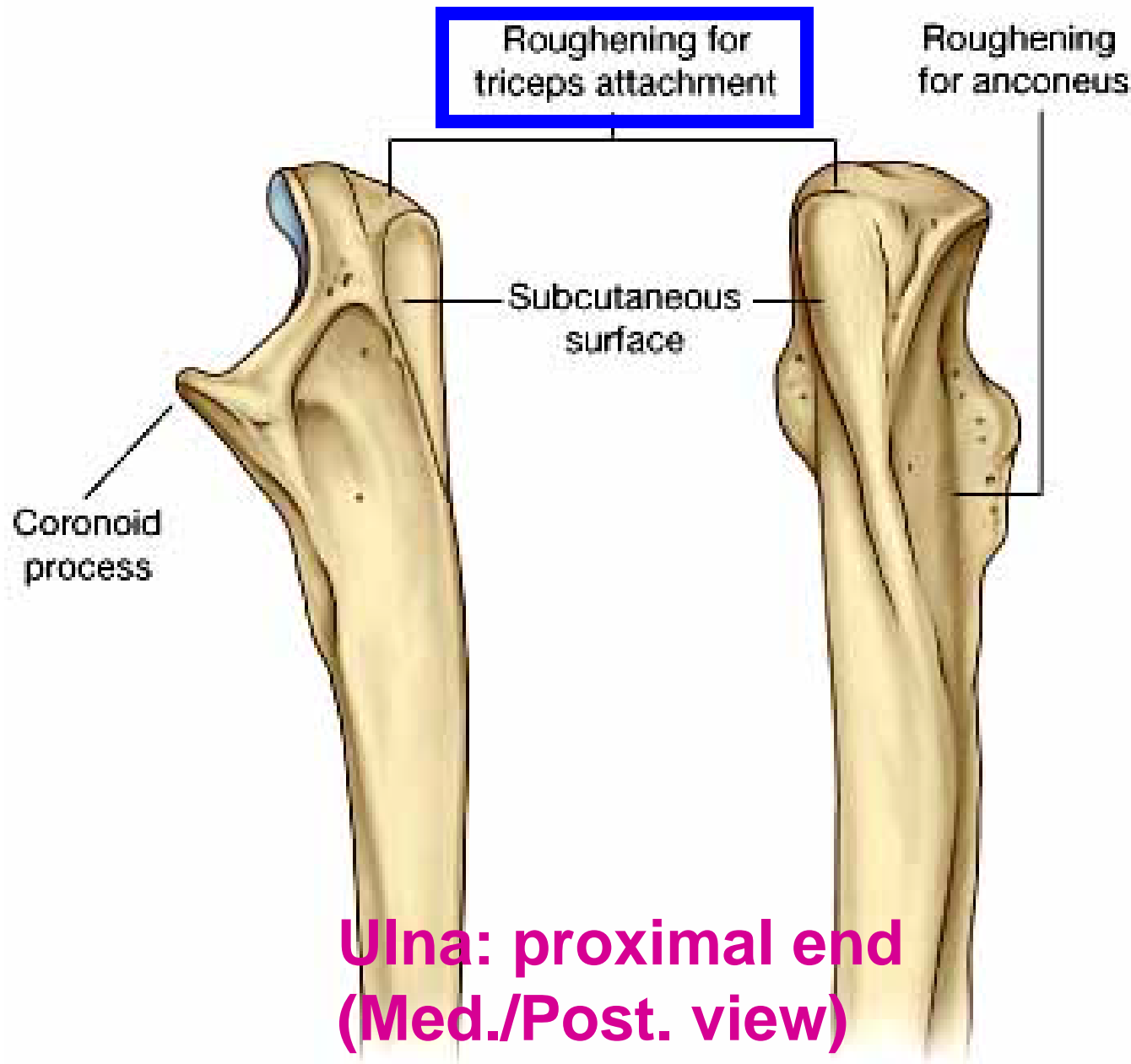
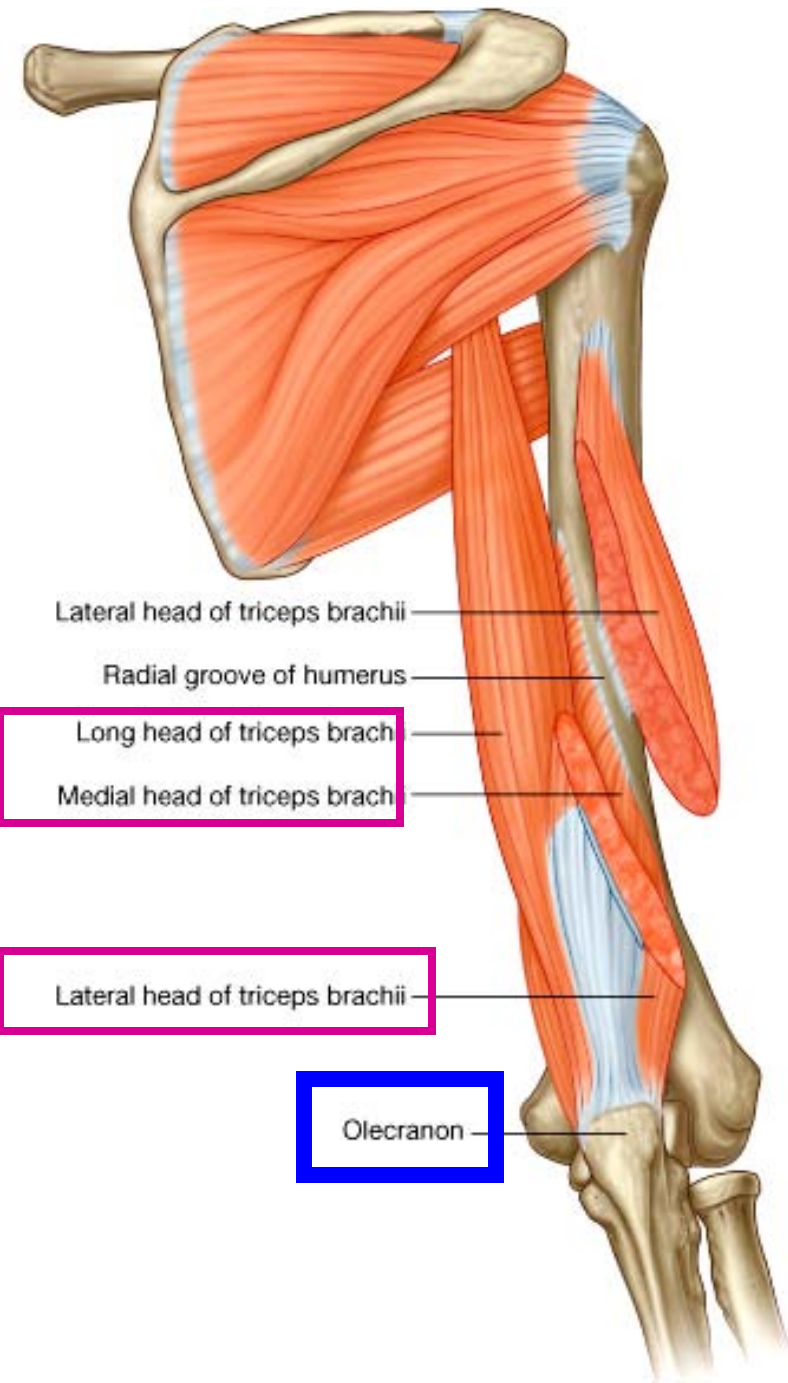


Posterior view: Right Humerus

Ulna: proximal end

- Trochlear notch
- Olecranon: anterior surface forming
- Coronoid process
- Radial notch: lateral surface
- Tuberosity of ulna for brachialis m.



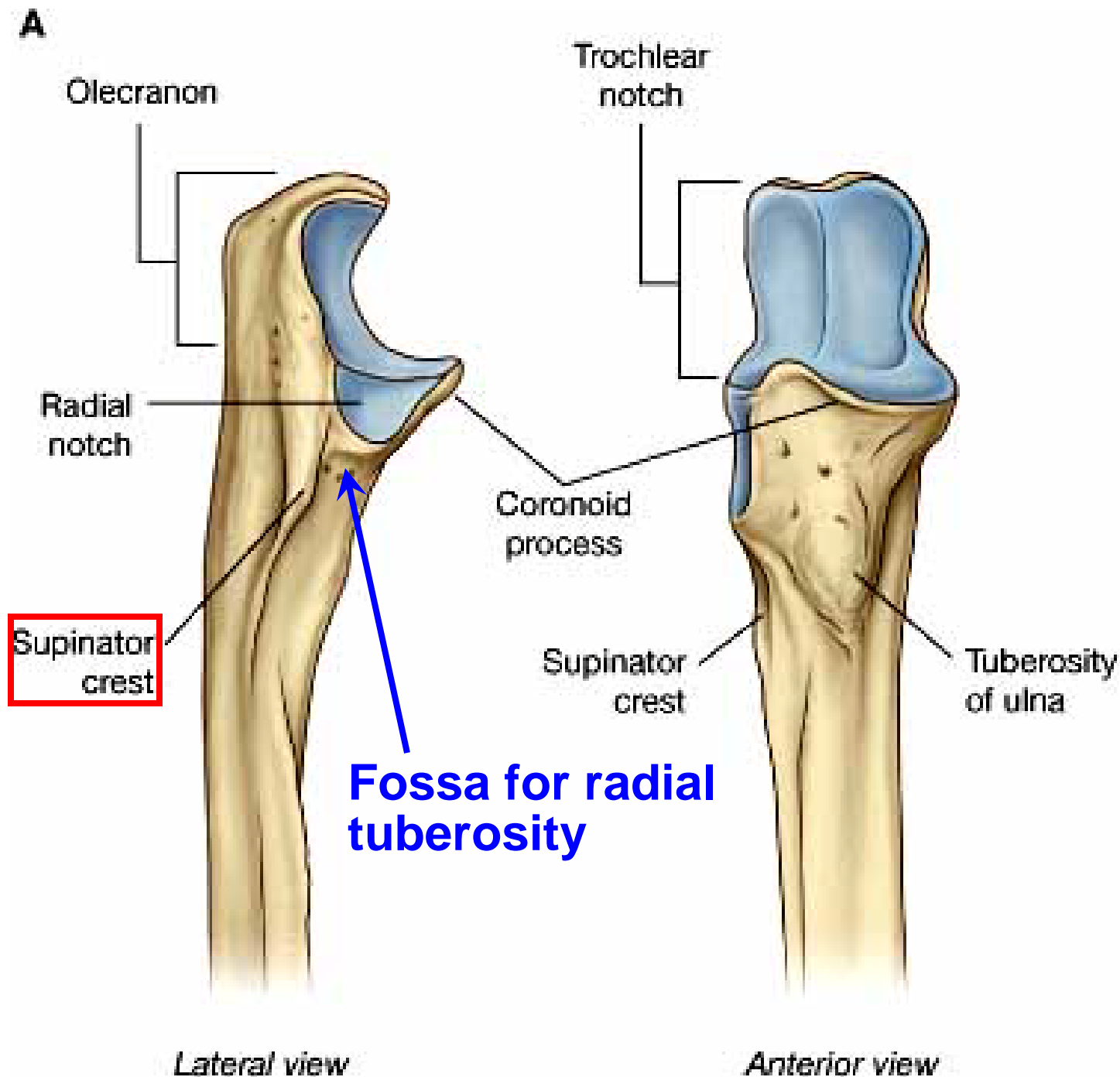


Medial view

Posterior view

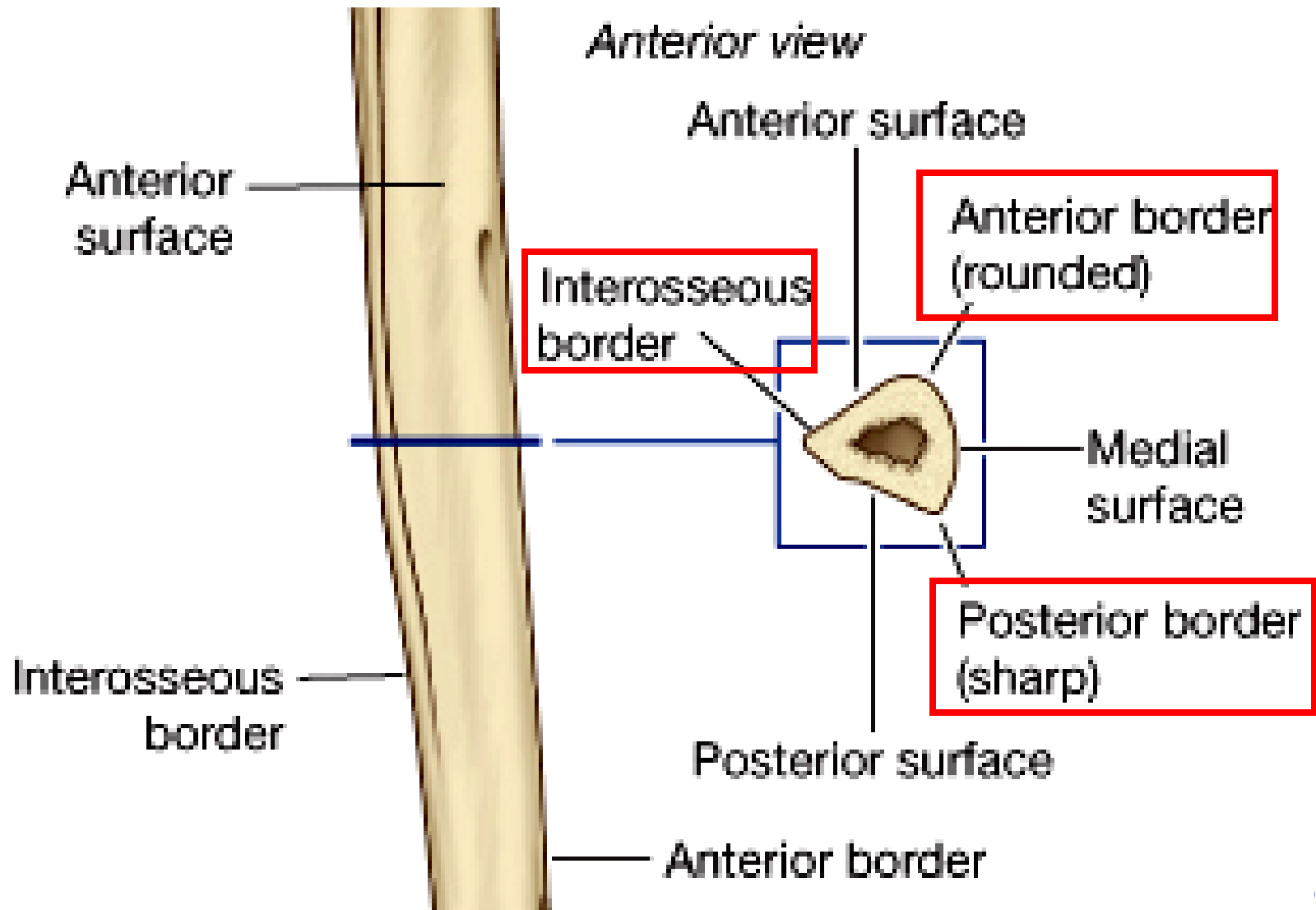
Ulna: prox. end (Lat. /Post. view)

- Radial notch for head of radius
- Fossa for radial tuberosity: inferior to radial notch for pronation / supination
- Supinator crest



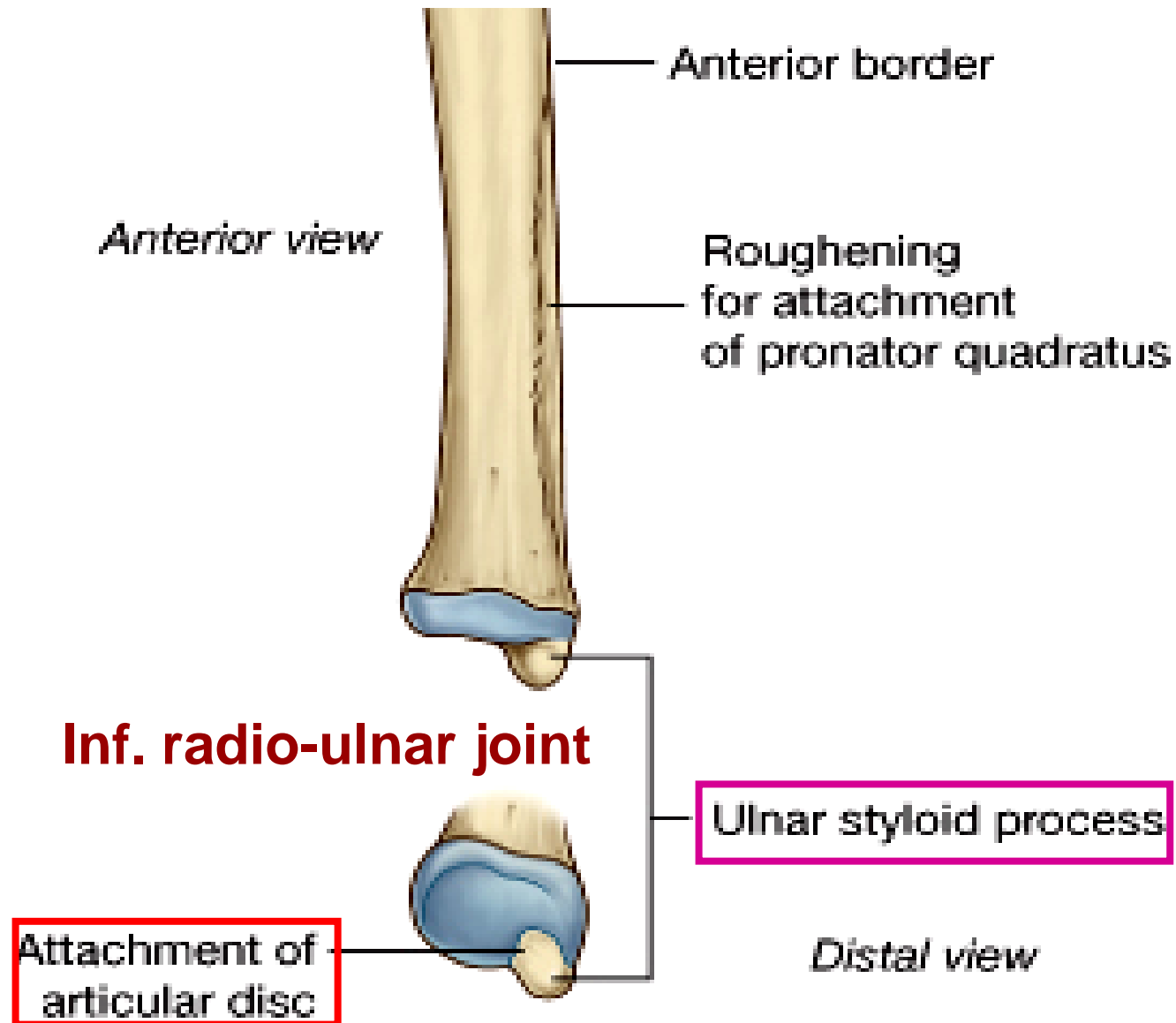
Ulna: Shaft

- triangular in cross section: **interosseous border**; ant. border; posterior border: subcutaneous (distally to styloid proc.)



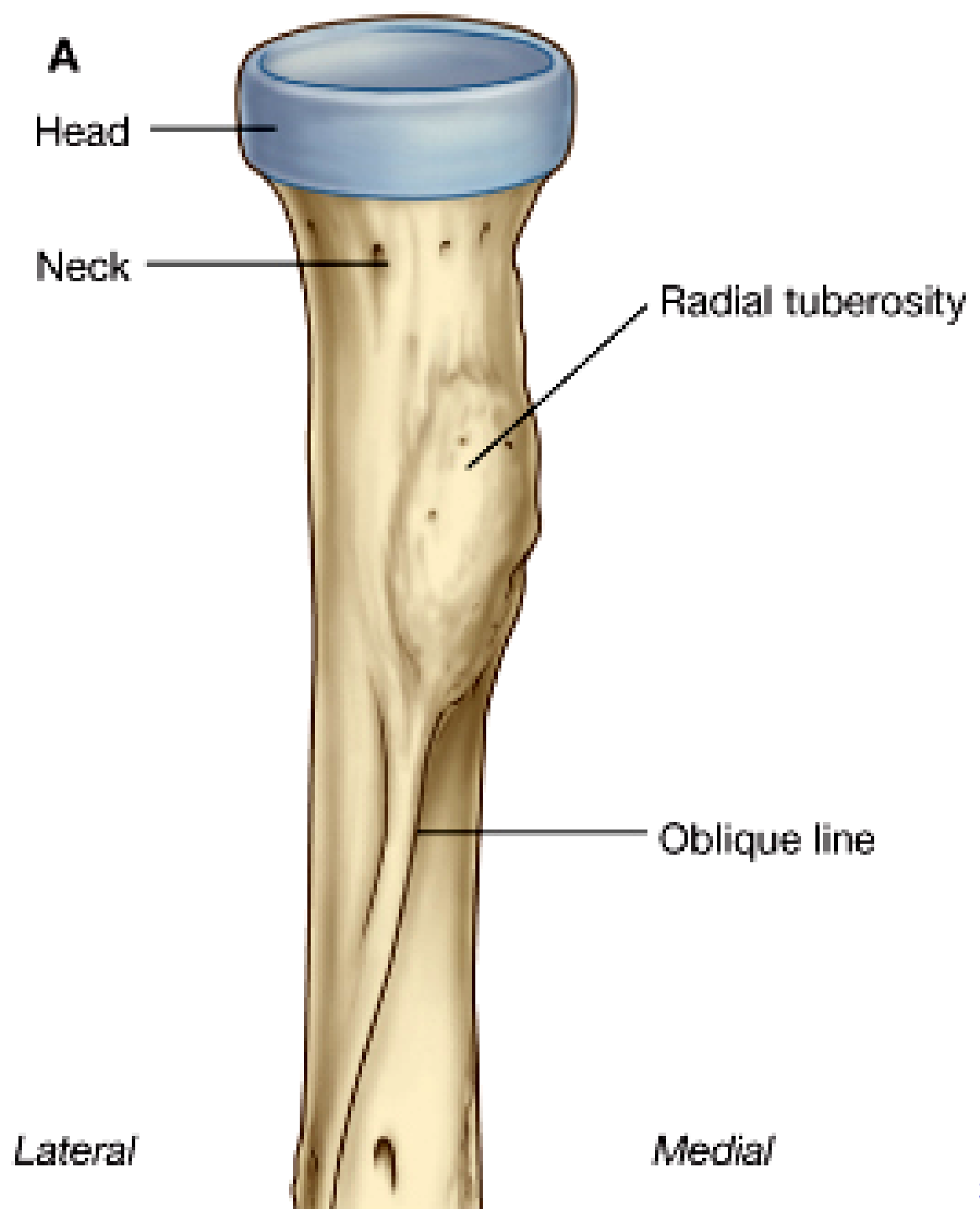
Ulna: Distal end

- **styloid process**
- **inf. radio-ulnar joint**
- articular disc of radiocarpal joint attaches to the base of styloid proc.

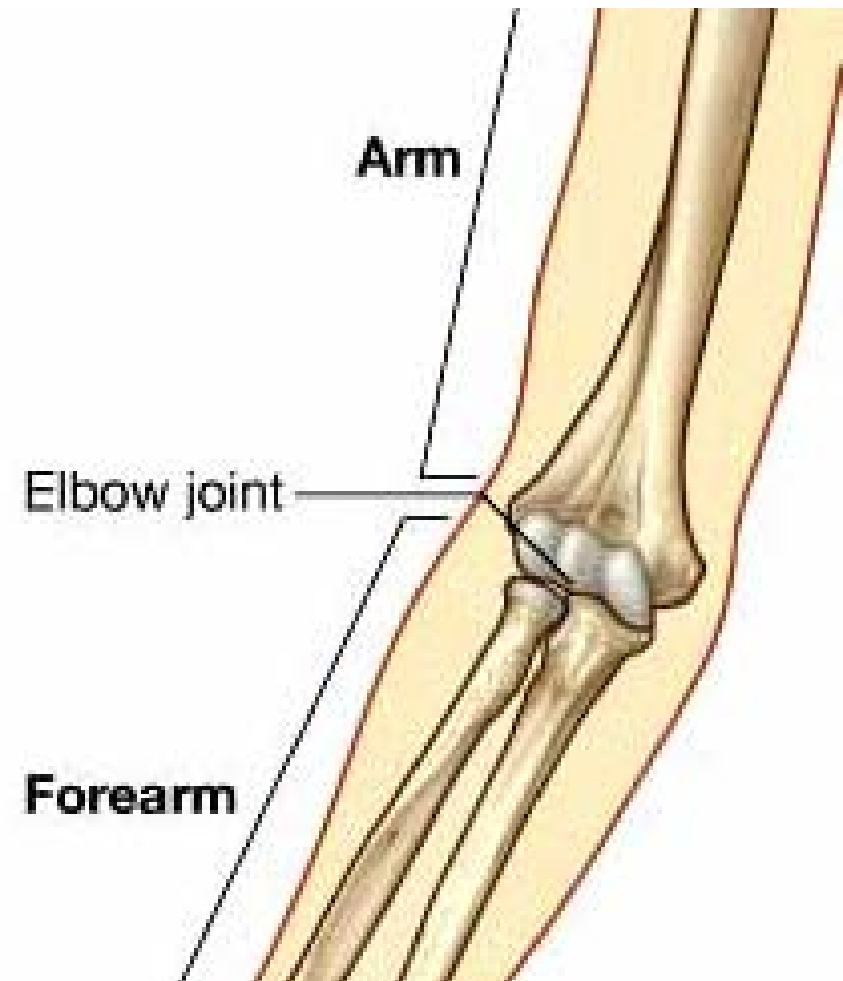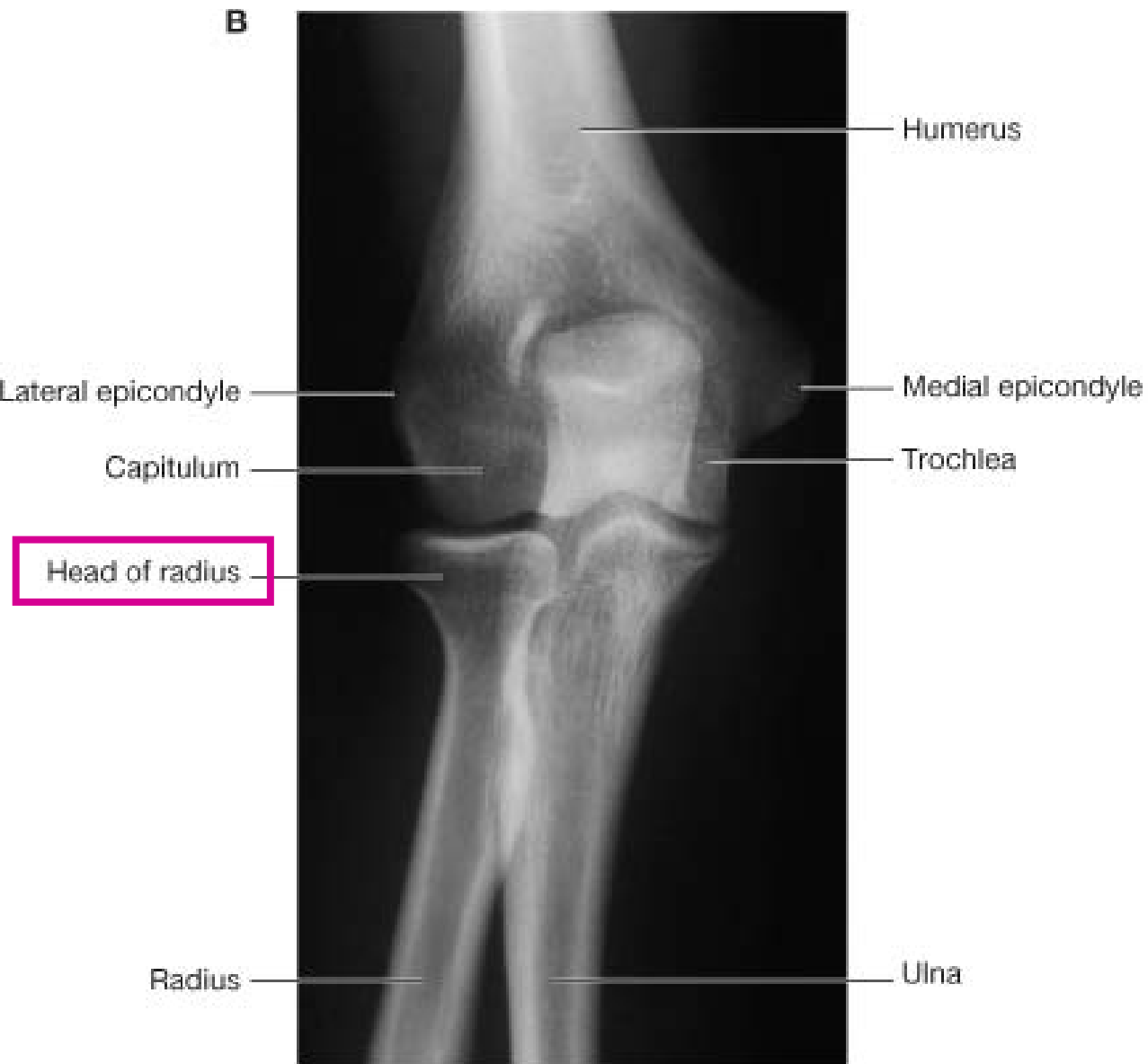


Radius: proximal end-1

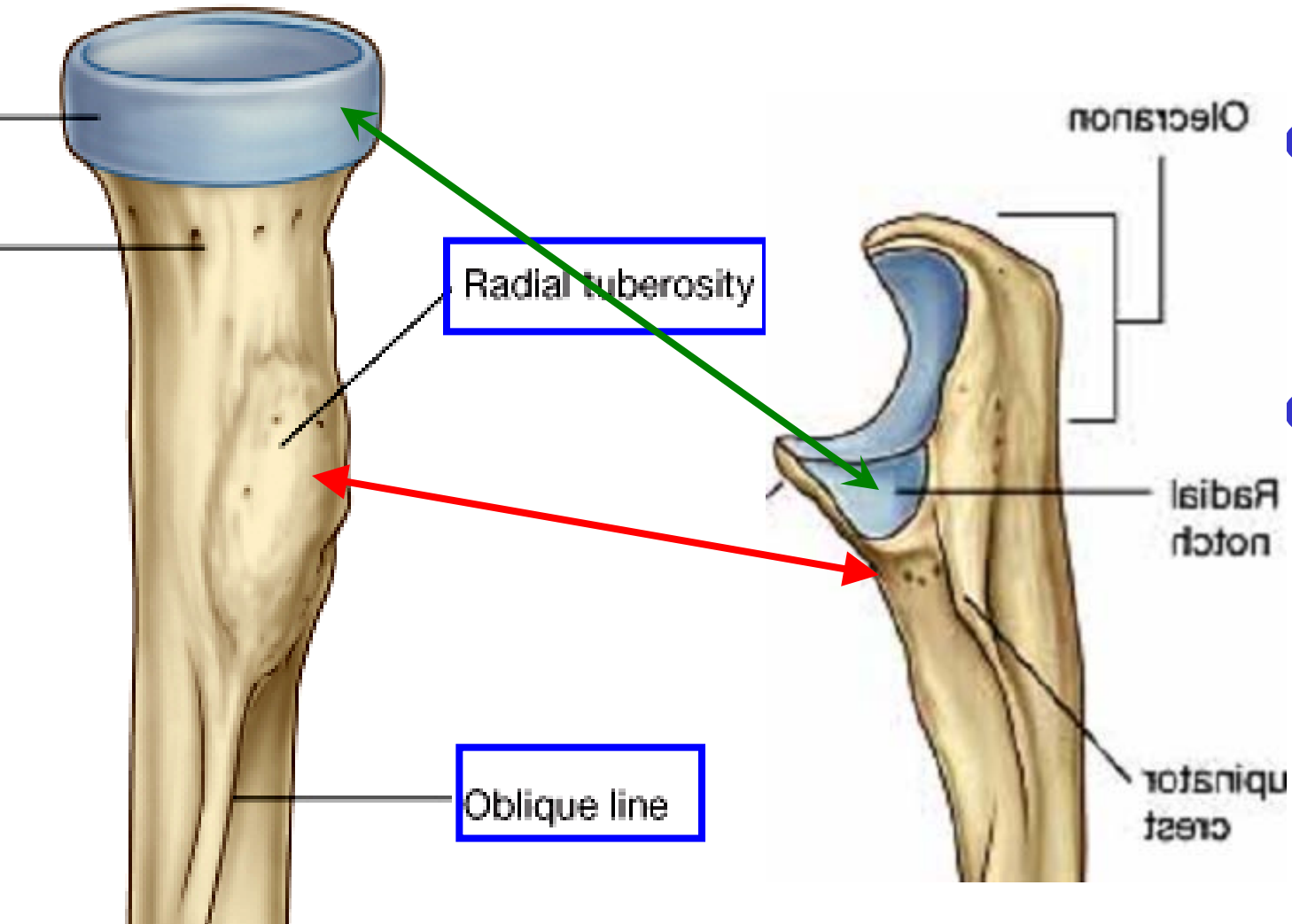
- Head
 - Disc-shaped in horizontal plane
 - Circular, superior, with capitum
 - Broad medially, with radial notch of ulnar
- Neck
 - Between head and radial tuberosity



Radius and humerus

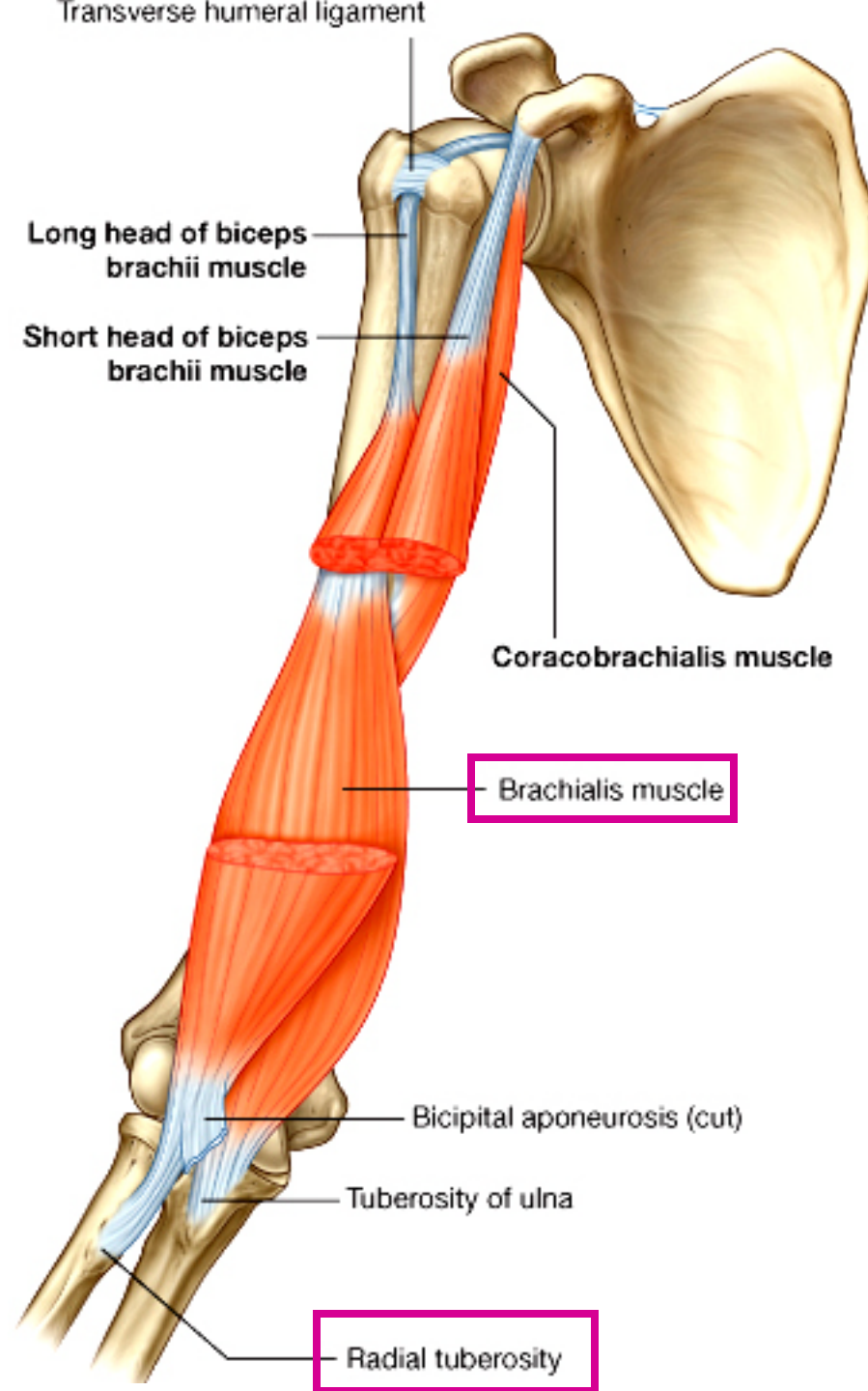


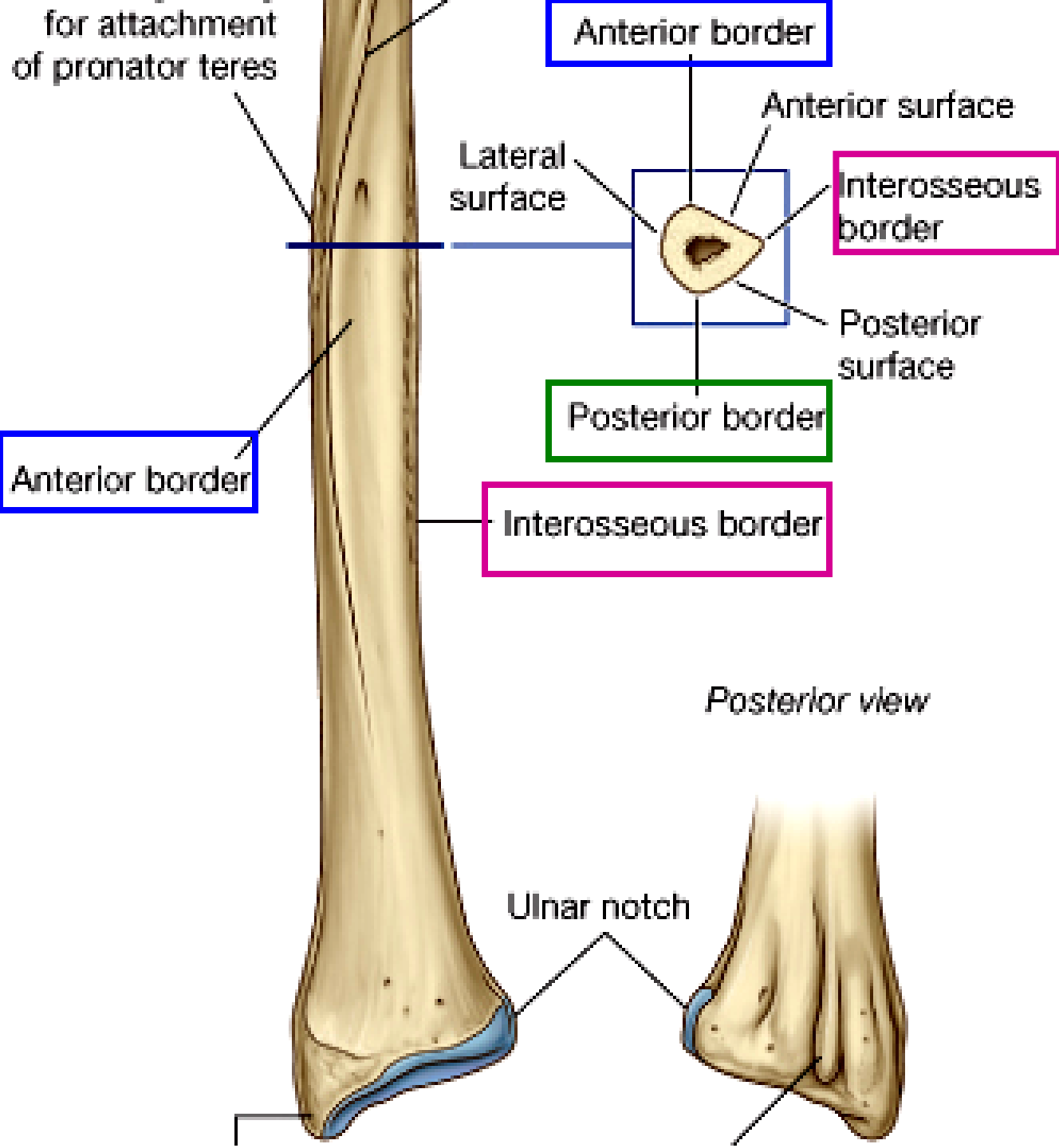
Radius: proximal end-2



- Radial tuberosity
 - For biceps brachii
- Oblique line
 - Continues diagonally from tuberosity

Radial tuberosity and Biceps brachii



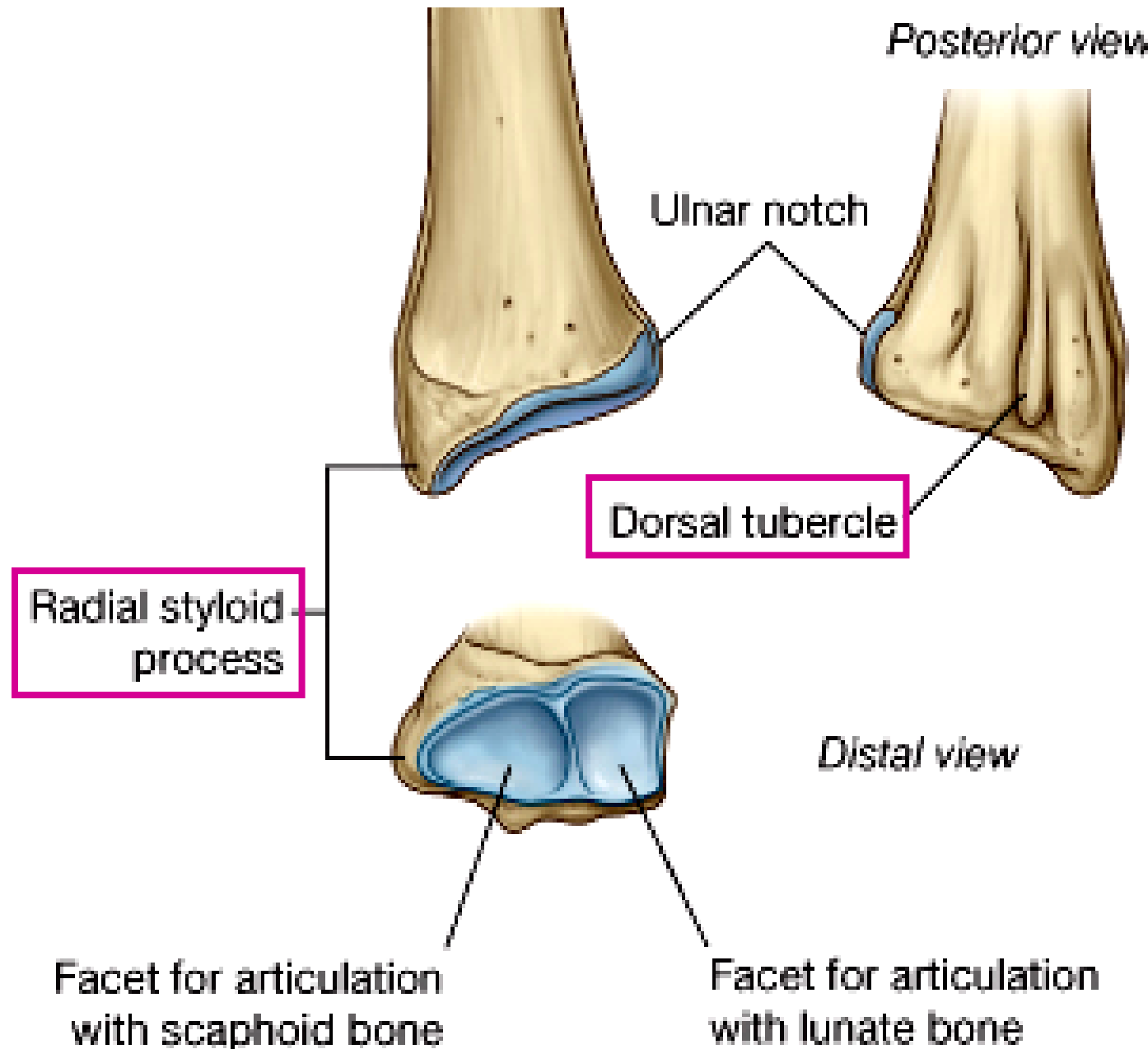


Radius: Shaft

- curved and convex laterally
- triangular shape in cross section
- **Interosseous border; Ant. border; Post. border**

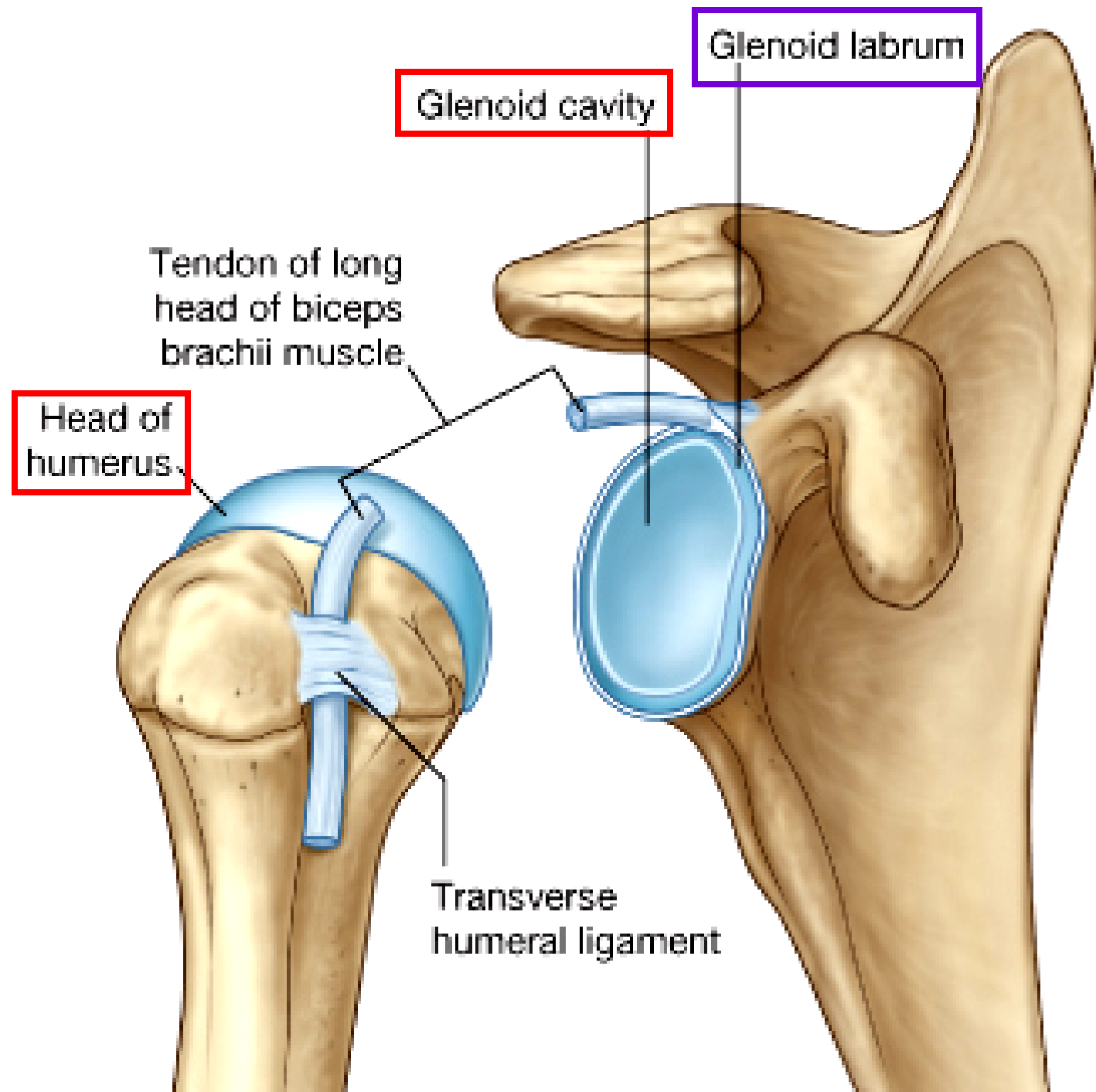
Radius: Distal end

- quadrangular in cross section; concave distal end for wrist joint
- styloid process: 1-2 cm lower than the styloid process of Ulna
- dorsal tubercle on post. surface: tendon of extensor pollicis longus loops at here



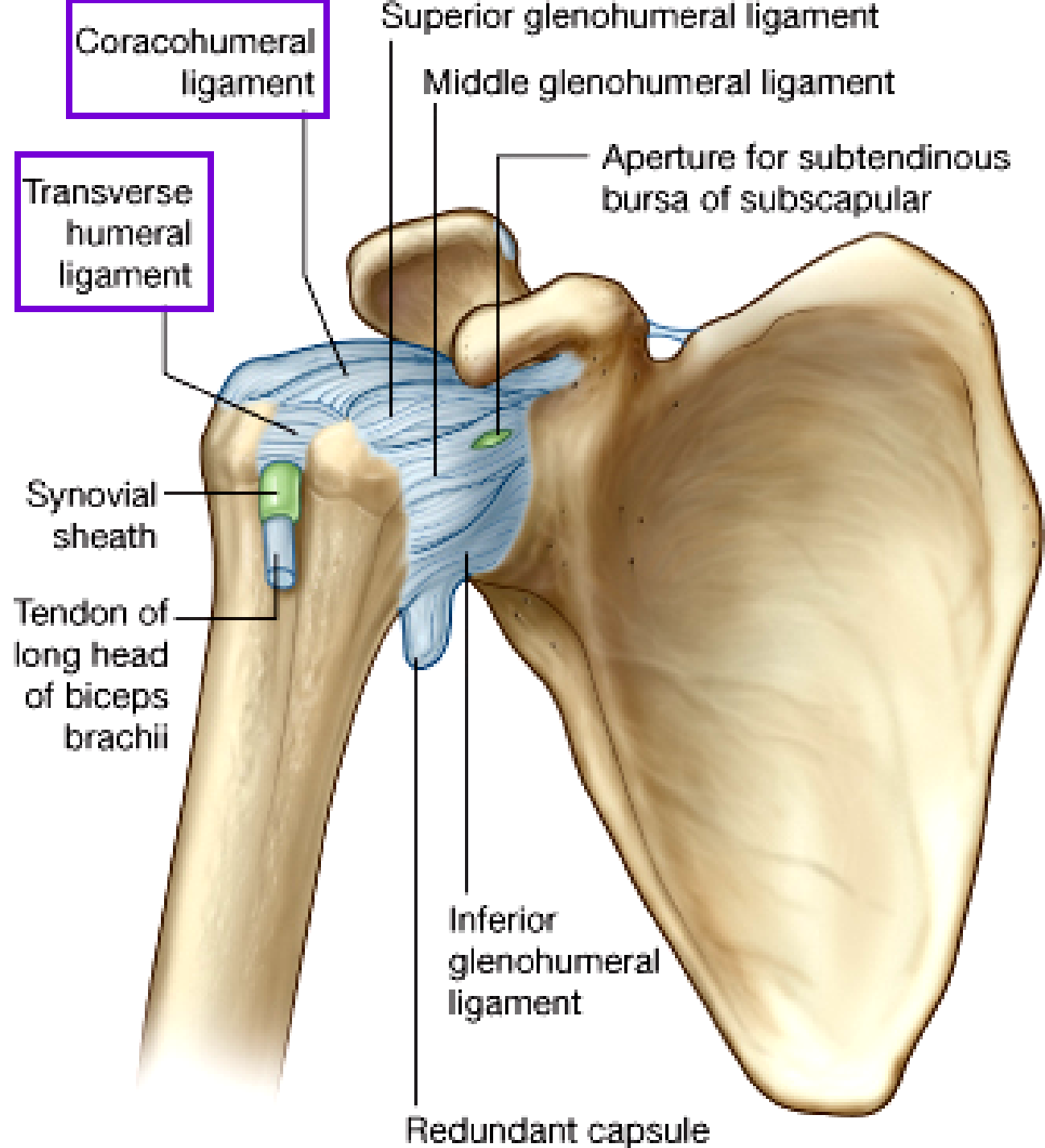
Shoulder joint (GlenoHumeral ligament)

- Glenoid labrum:
- fibrocartilage
- Glenoid cavity
- Humeral head



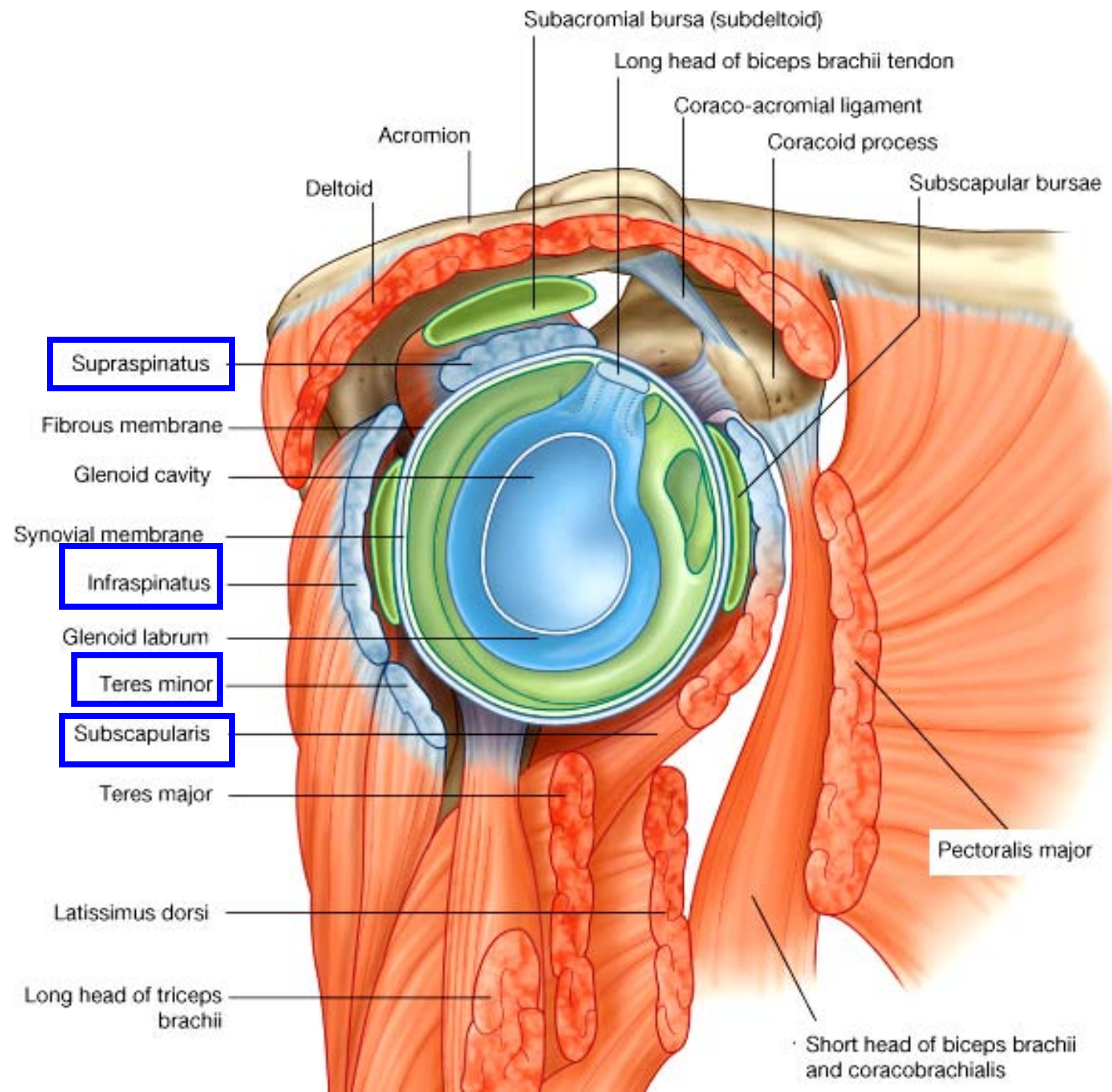
Shoulder joint

- Transverse humeral lig.: bicipital groove
- Coracohumeral lig.

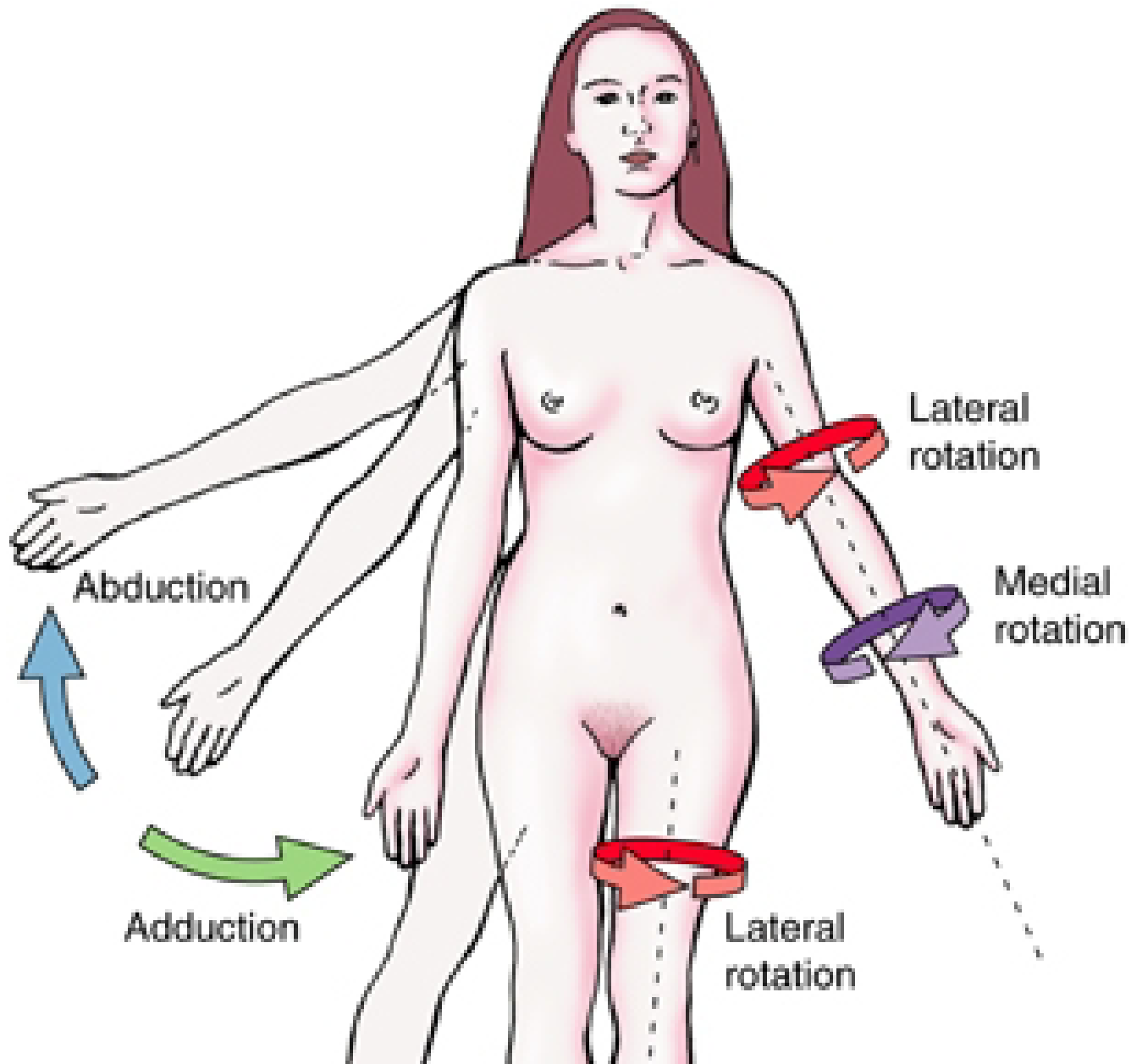


Rotator cuff

- Supraspinatus
- Infraspinatus
- Teres minor
- Subscapularis

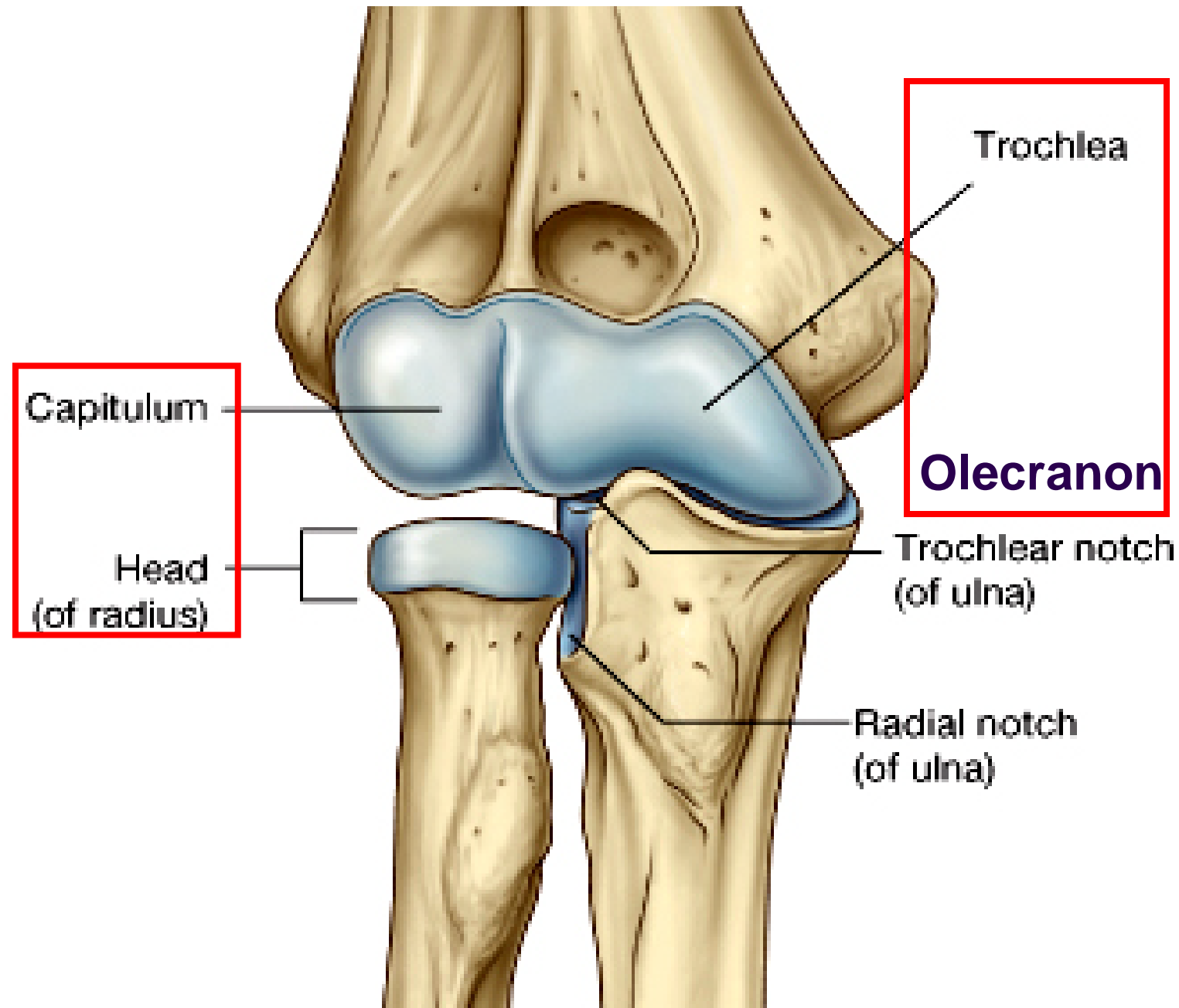


Movements of shoulder girdle



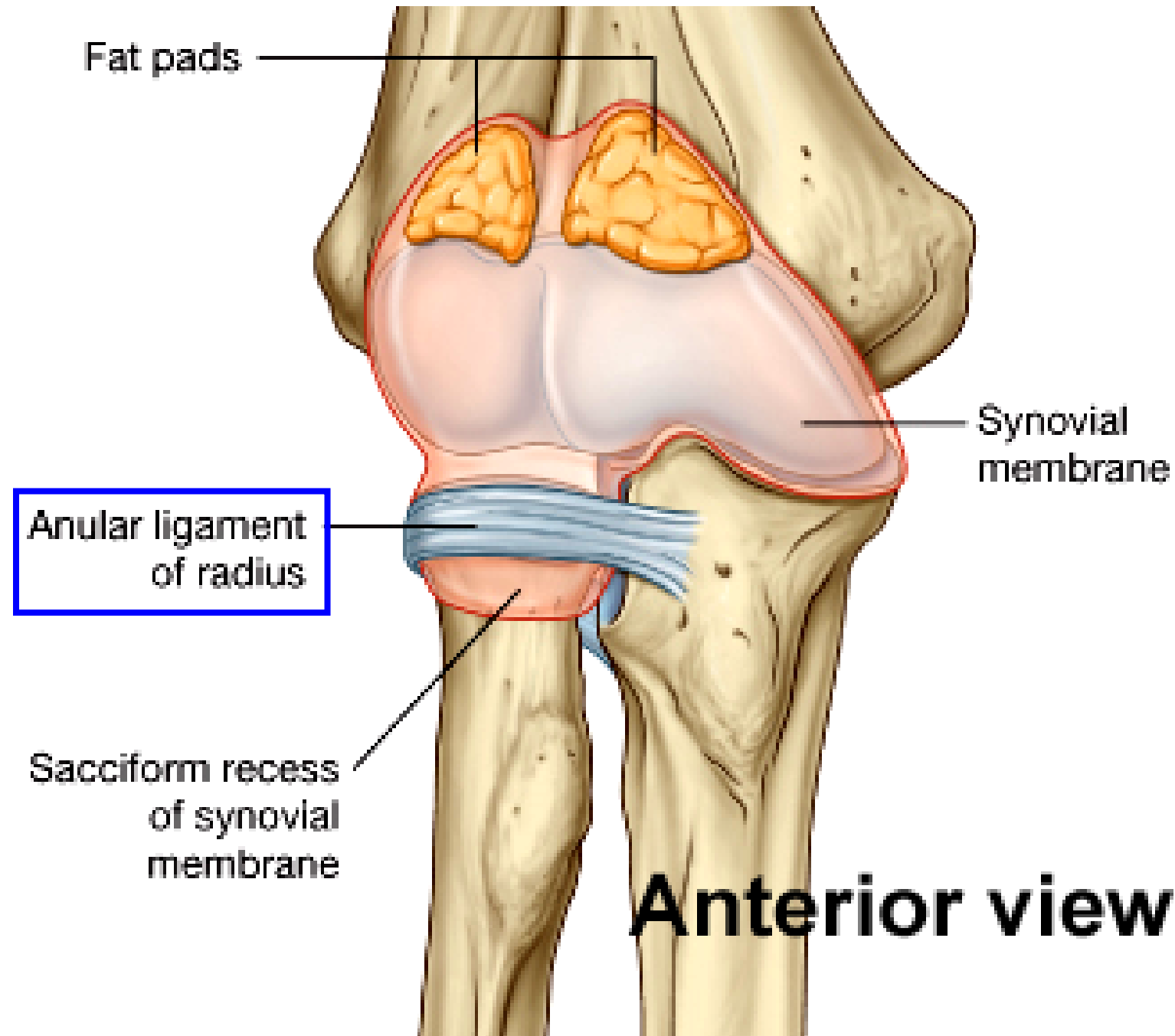
Elbow joint

- Capitulum:
Head of radius
- Trochlea:
Olecranon



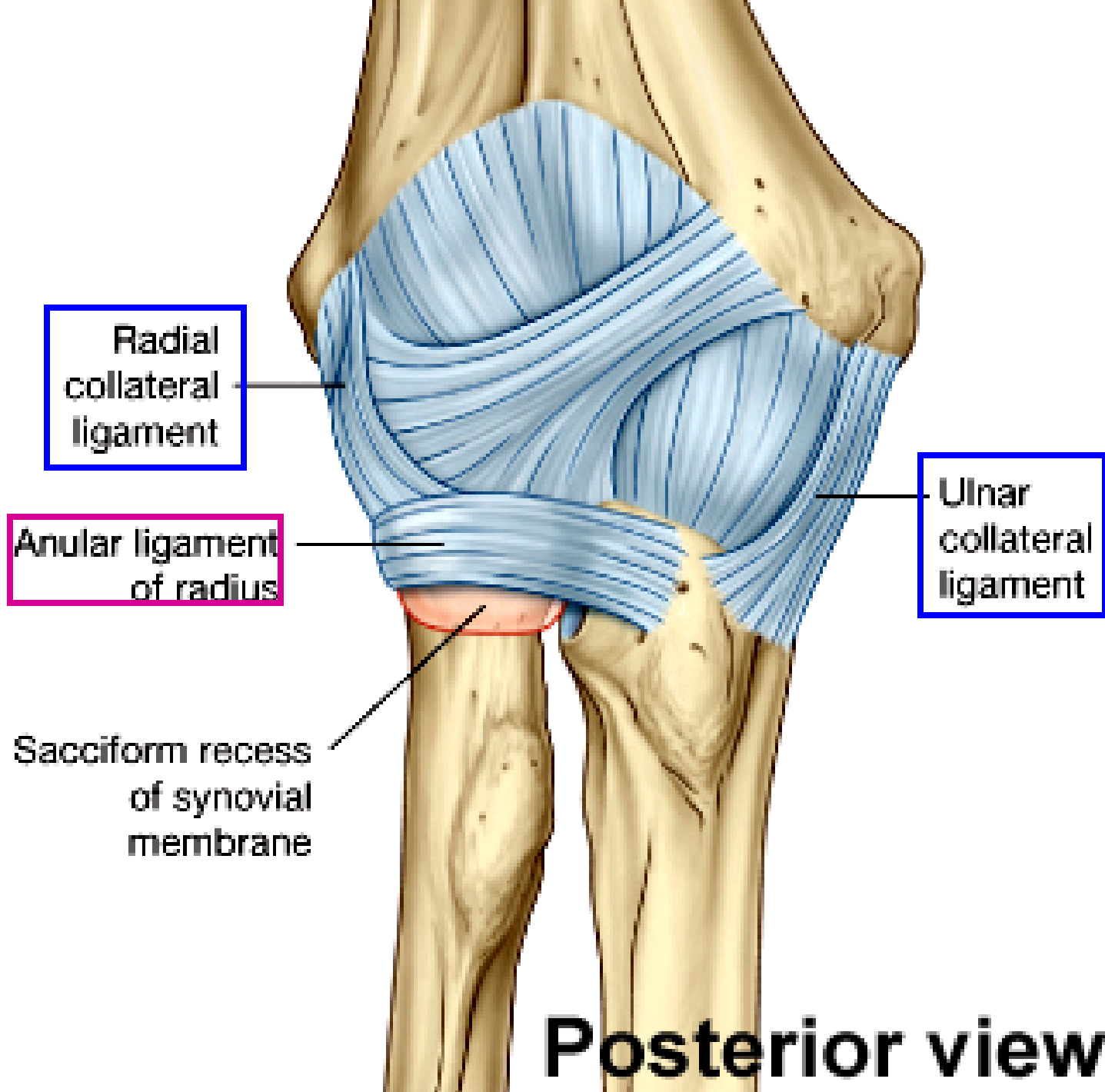
Elbow joint

- Annular lig.:
head of
radius to
radial notch;
4/5 ring

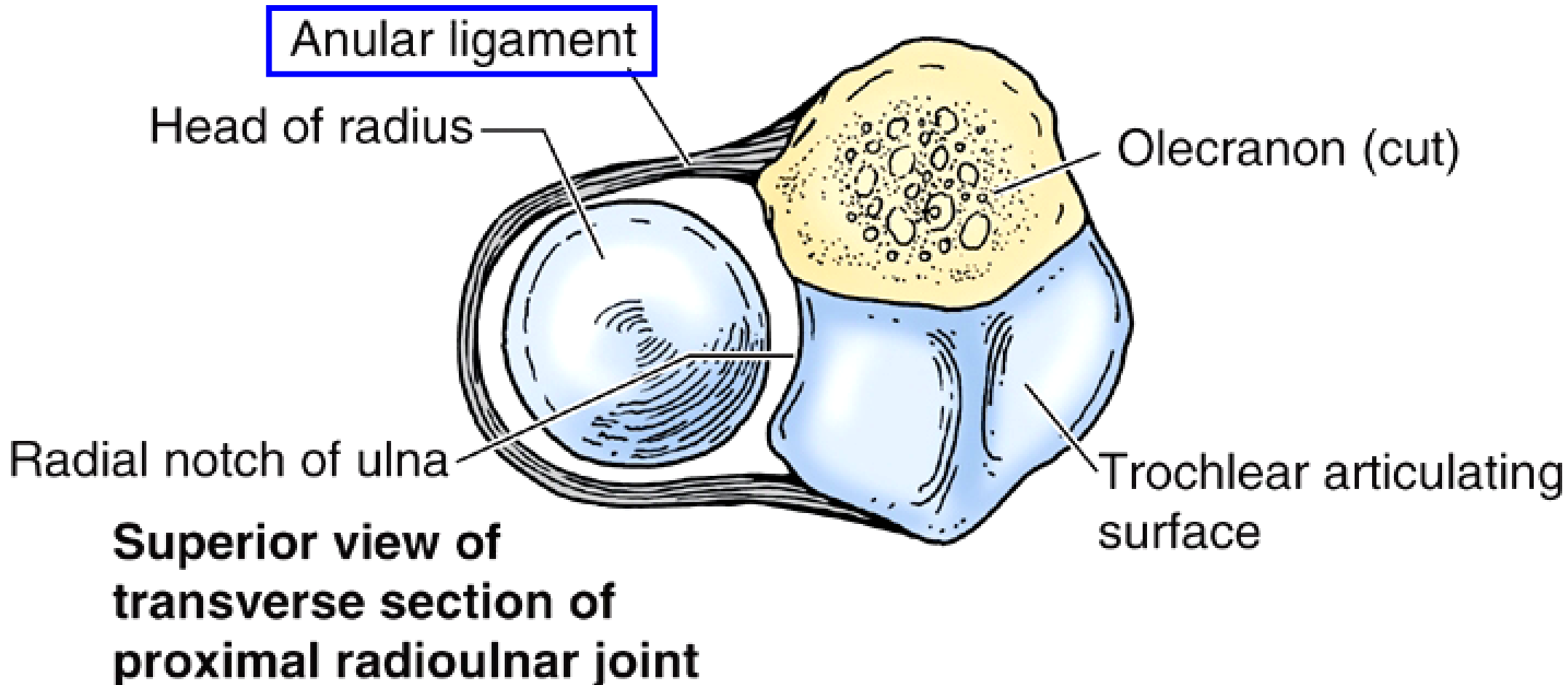


Elbow joint

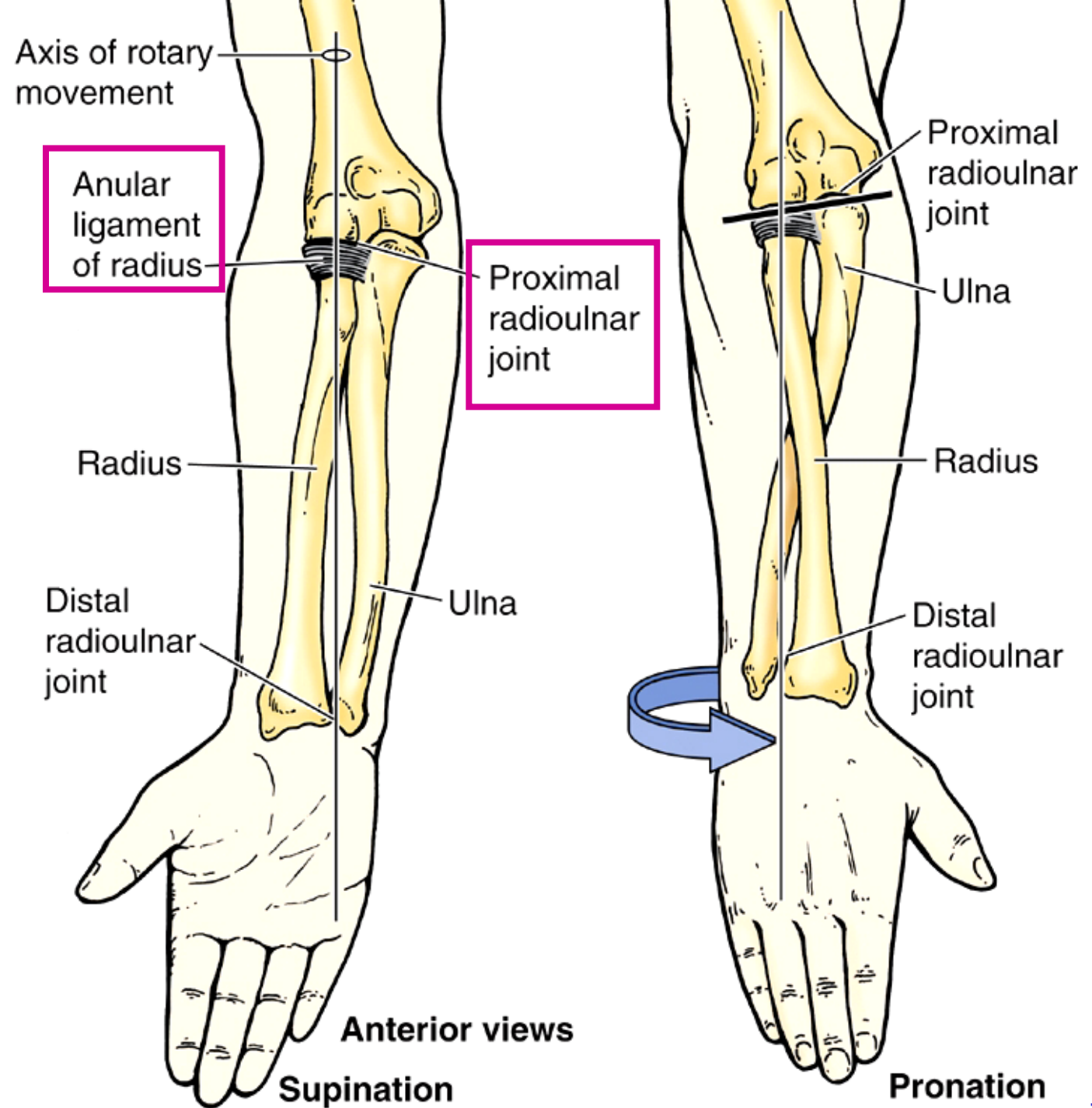
- Annular lig.
- Radial collateral lig.
- Ulnar collateral lig.



RadioUlnar joint

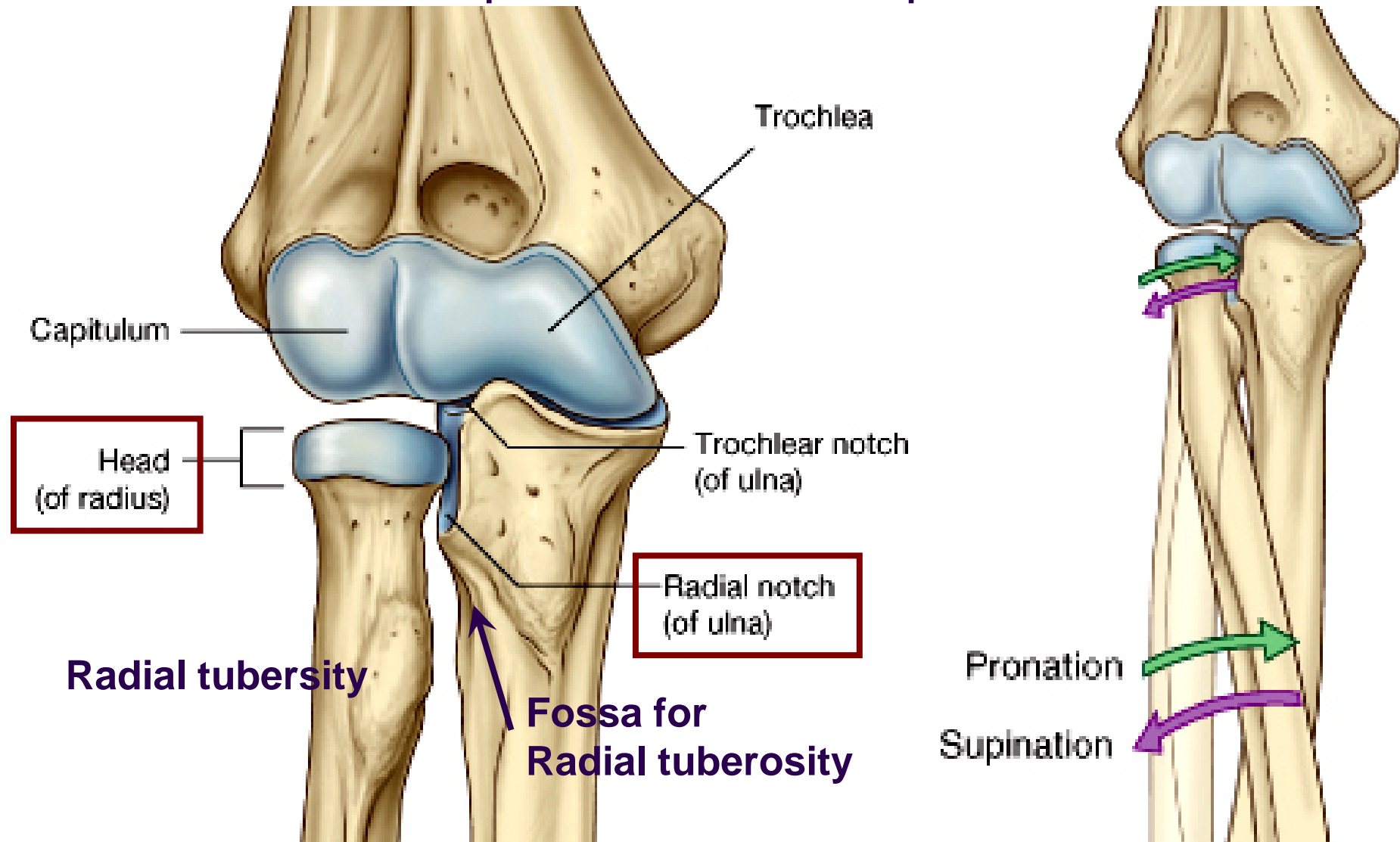


RadioUlnar joint



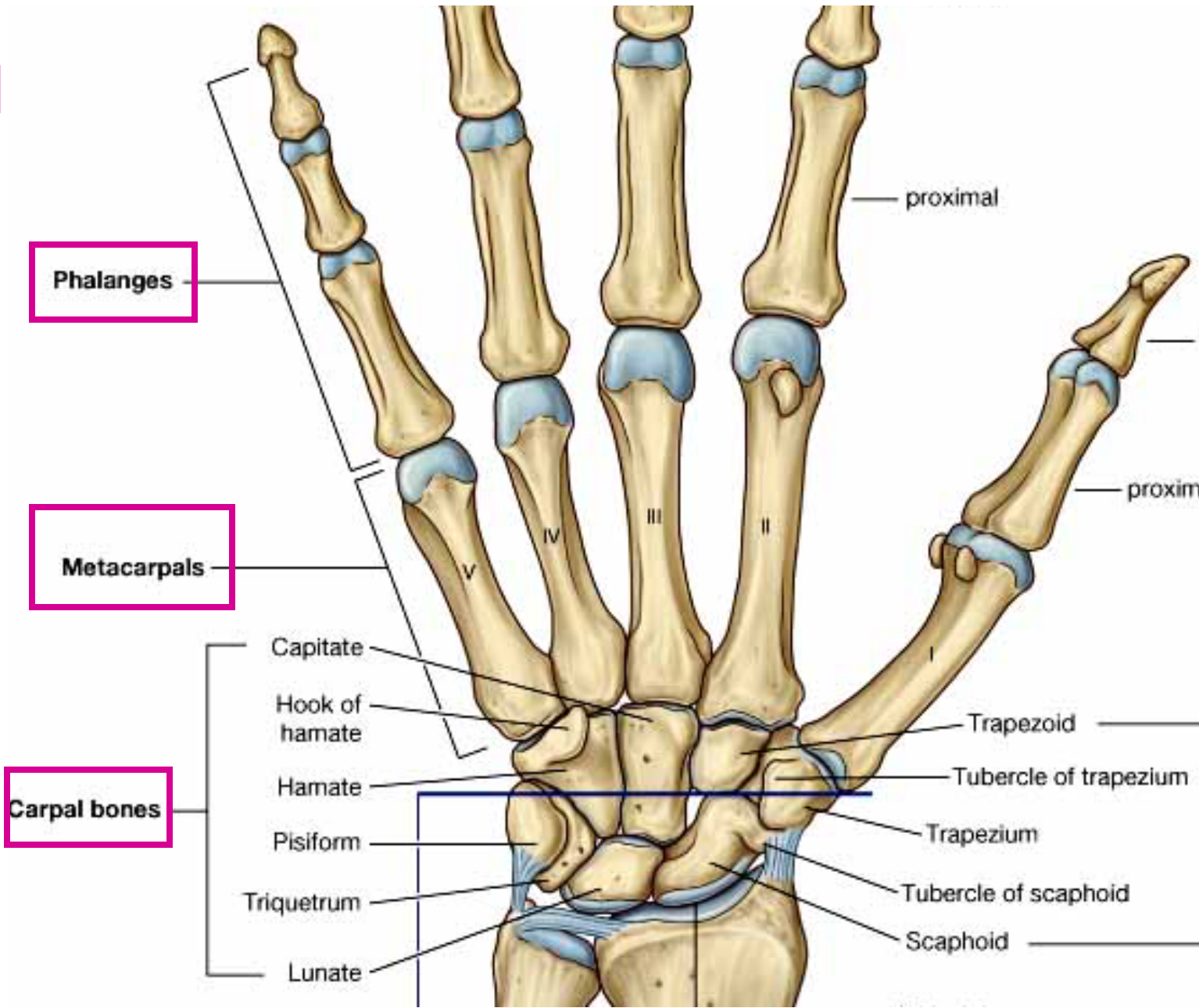
Radio-Ulnar joint: Proximal

- Sup. radio-ulnar joint: between Head of radius and Radial notch of ulna; for pronation and supination



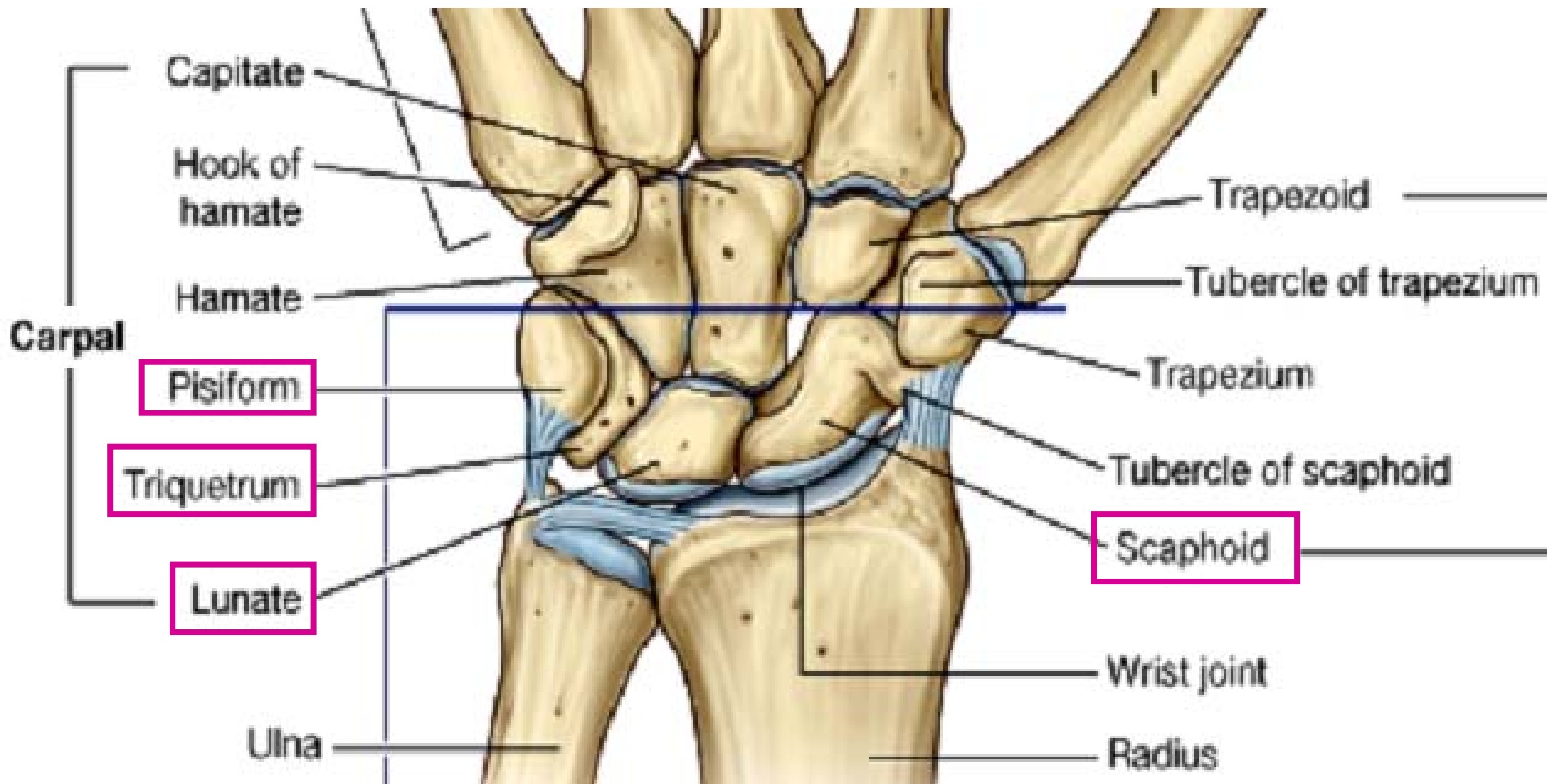
Bones of Hand

- Carpal bones
- Metacarpals
- Phalanges



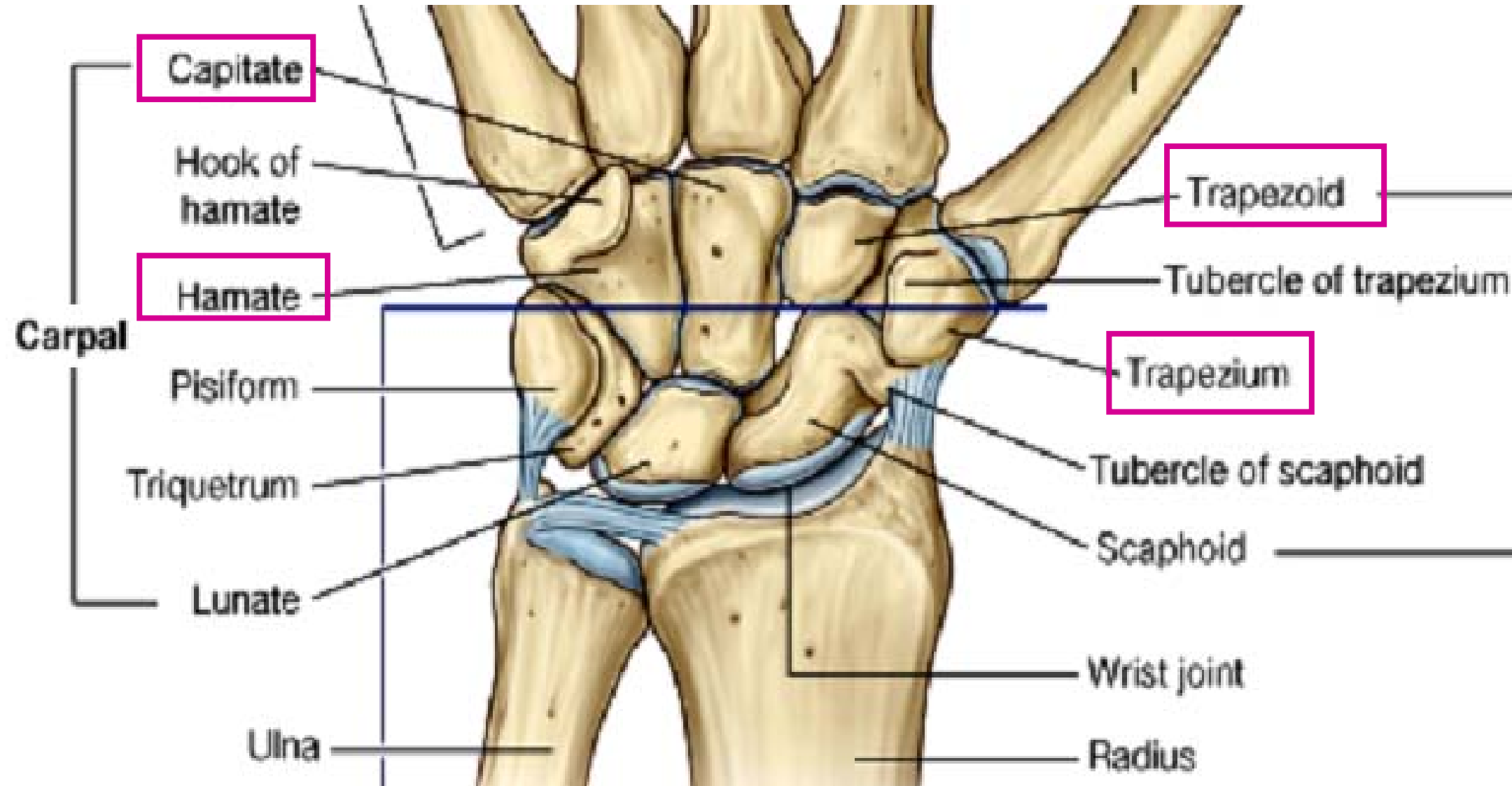
Carpal bones: proximal row (rad. side → ulnar side)

- scaphoid, lunate, triquetrum (triquetrum), pisiform



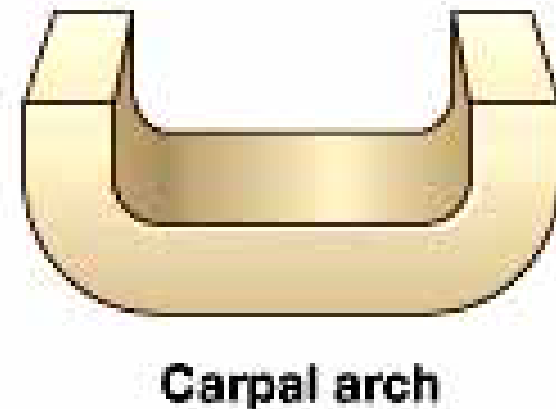
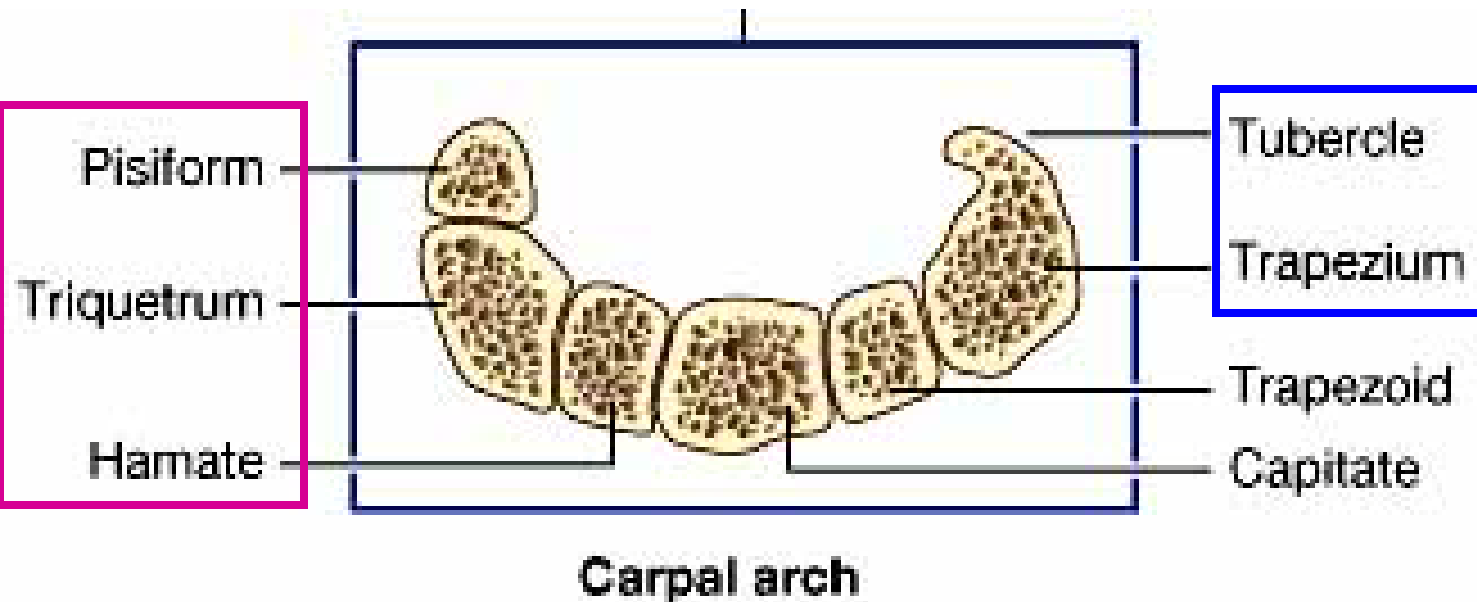
Carpal bones: distal row (rad. side → ulnar side)

- trapezium, trapezoid, capitate, hamate

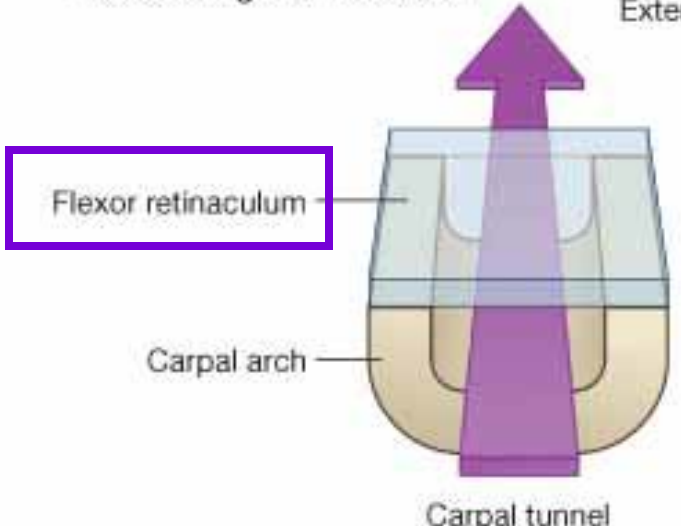
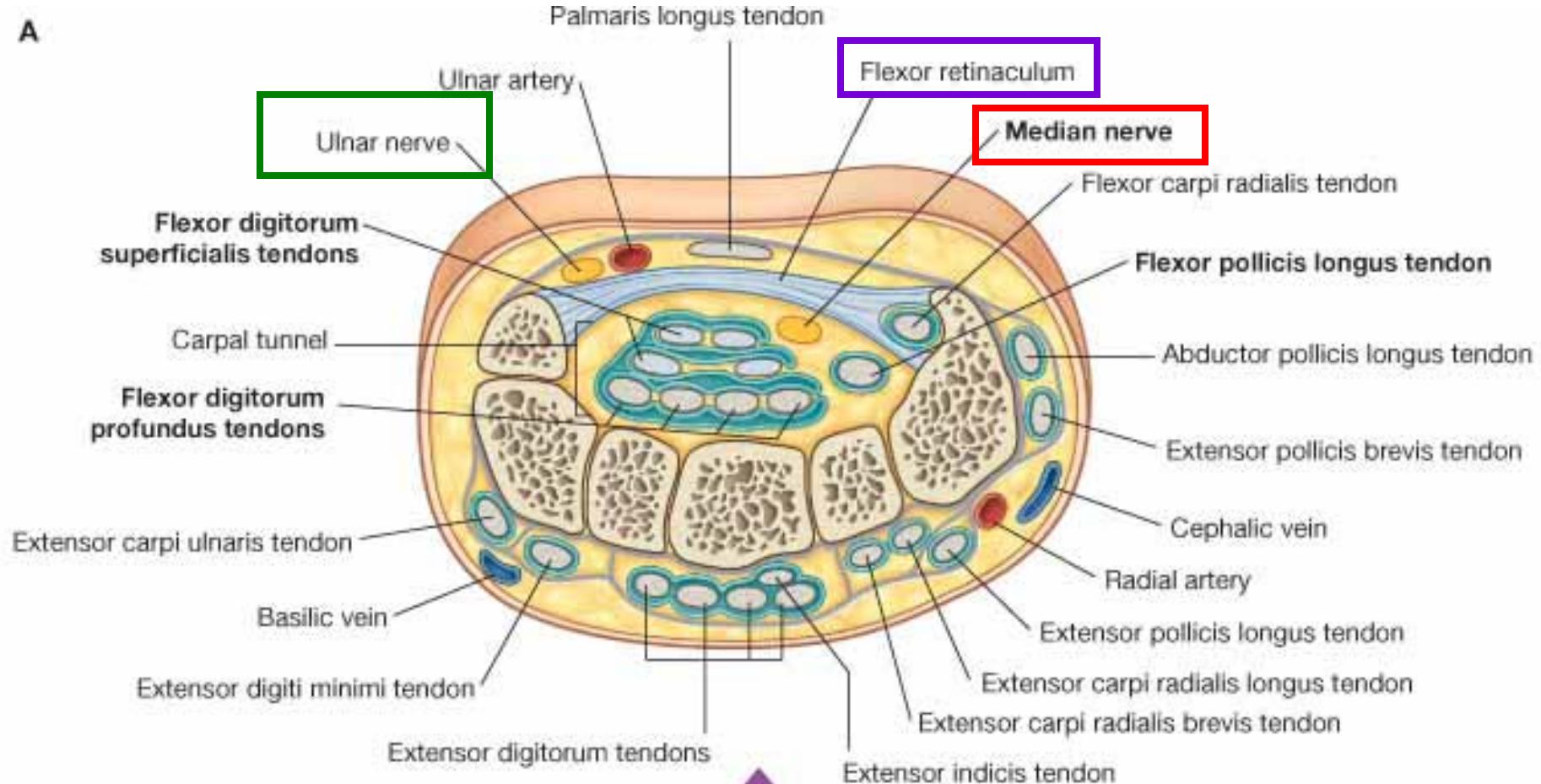


Carpal arch; Carpal tunnel

- Laterally: **tubercles of scaphoid, trapezium**
- Medially: **pisiform, triquetrum, hook (hamulus) of hamate**
- **flexor retinaculum; carpal tunnel** (long flexor tendons + median n.)



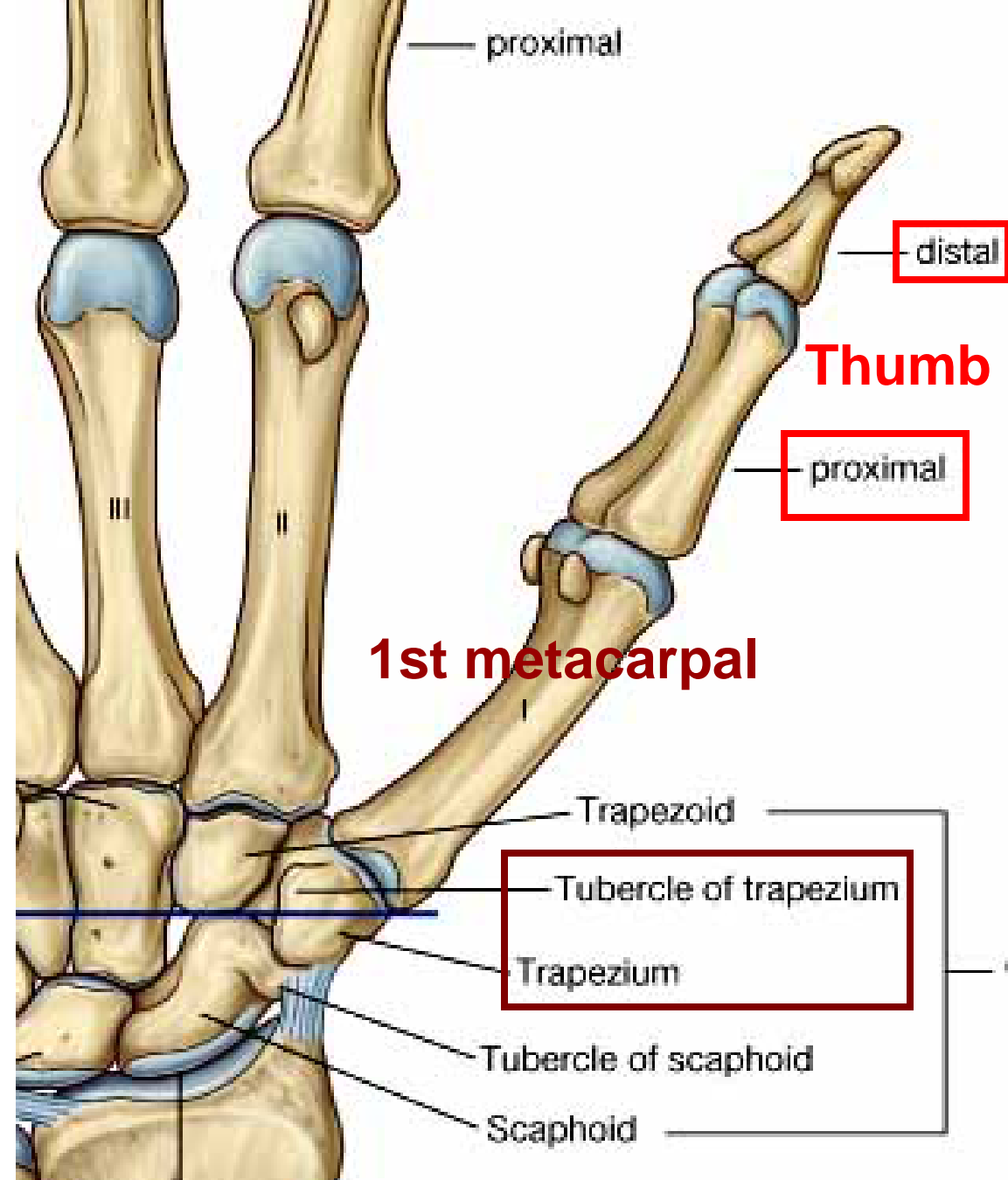
A



Carpal tunnel

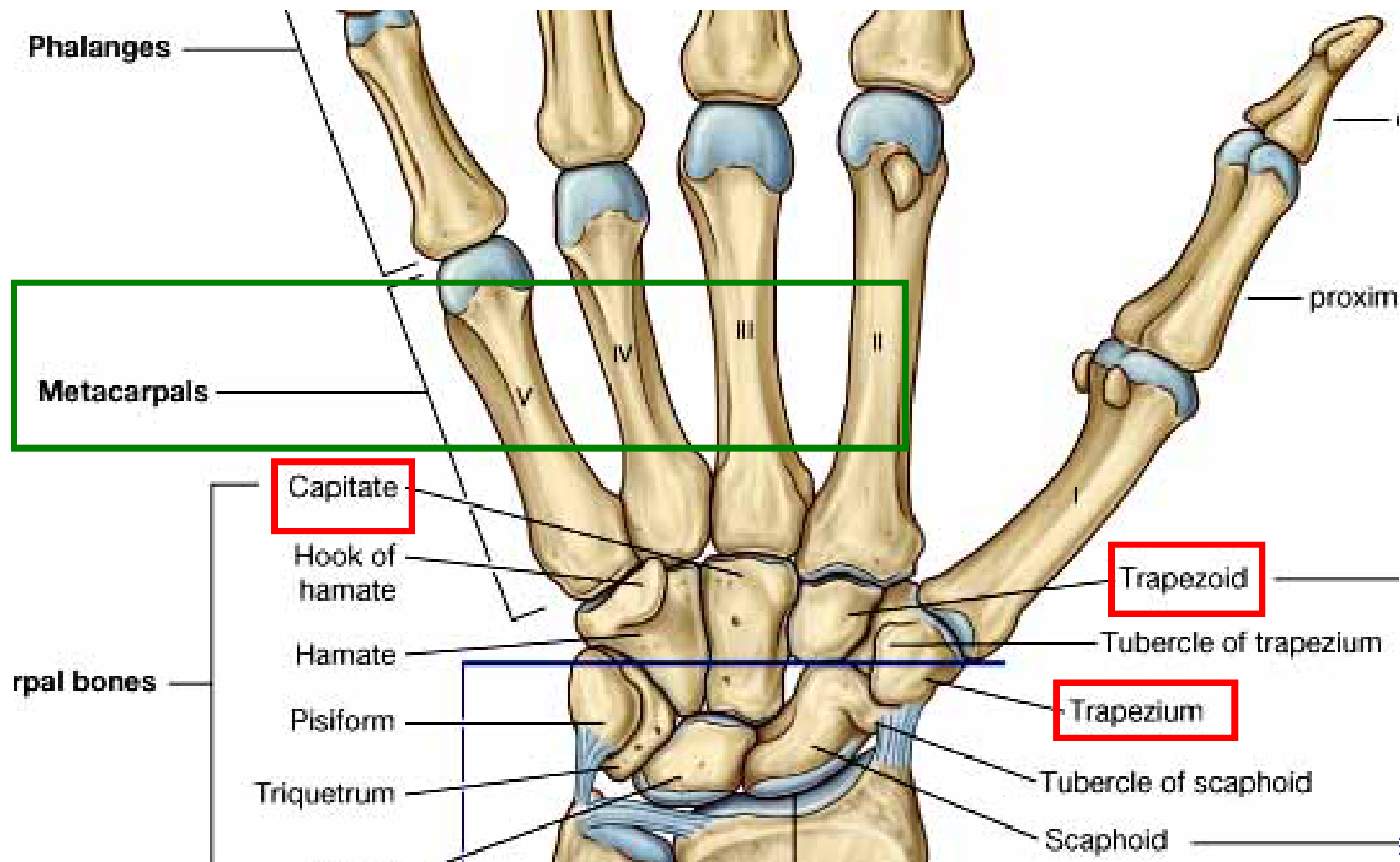
1st metacarpal

- articulates with trapezium: **saddle joint**
- thumb: proximal and distal phalanges face medially; action: flex./ext.; abd./add.
- metacarpophalangeal and interphalangeal joint with strong collateral lig.



2nd-5th metacarpals

- **2nd metacarpal:** articulates with trapezium, trapezoid, capitate, and base of 3rd metacarpal
- firmly held, no independent movement with carpal bone



Phalanges

A

- Phalanx: base, shaft (body), head
- Thumb: proximal, distal phalanx
- 2nd-5th digits: proximal, middle, distal phalanx

