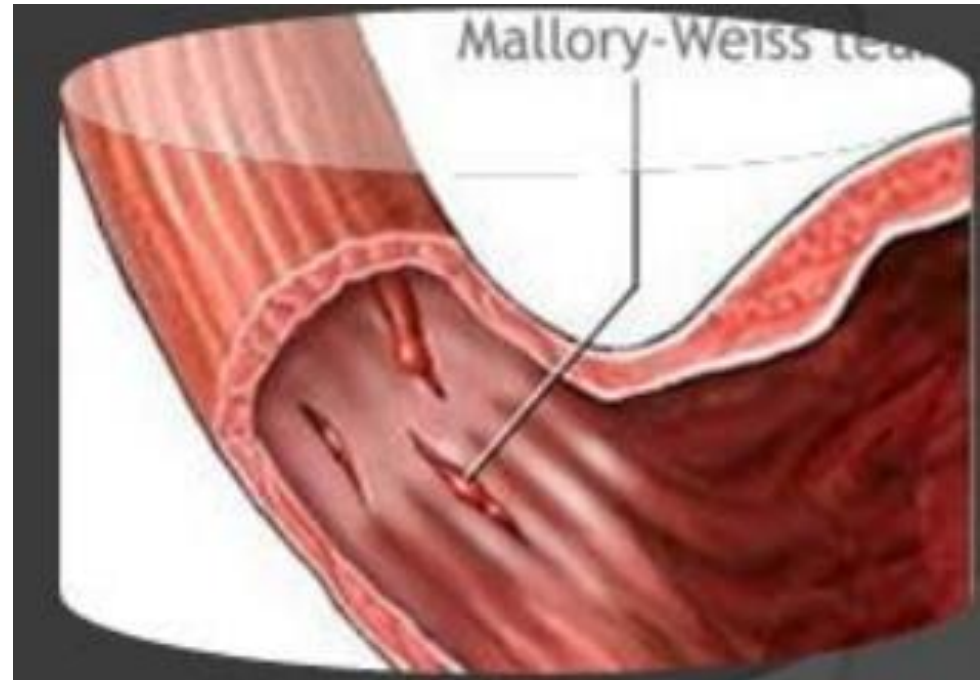


# Mallory- Weiss Syndrome

**Prof. Naveed Jabbar Bandesha**  
**Chairman Department of Surgery & Allied**  
**SMC/UOS**  
**Sargodha**

# Mallory- Weiss Syndrome

- Painless hematemesis after vomiting & straining mostly by excessive alcohol intake
- High incidence of GORD
- Linear tear of mucosa or mucosa & submucosa close to OGJ
- More common in males



# Mallory- Weiss Syndrome

- Tear may be single or multiple
- Bleeding stops spontaneously in majority
- Located on lesser curve side in 85%
- stic
- Associated lesion as hiatal hernia , or duodenitis/ peptic ulcer
- But may be severe or recurrent

# Mallory- Weiss Syndrome

- OGD to confirm diagnosis
- Most settle without treatment
- Injection of adrenaline 1:10000
- Mechanical methods like banding or clipping not superior but good alternatives